

Antioxidant role of taurine and oyster mushroom on kidneys of male mice induced by paraquat herbicide

Endang Linirin Widiastuti, Endang Nurcahyani, and Bayu Putra Danan Jaya

Citation: *AIP Conference Proceedings* **2002**, 020021 (2018); doi: 10.1063/1.5050117

View online: <https://doi.org/10.1063/1.5050117>

View Table of Contents: <http://aip.scitation.org/toc/apc/2002/1>

Published by the *American Institute of Physics*

AIP | Conference Proceedings

Get **30% off** all
print proceedings!

Enter Promotion Code **PDF30** at checkout



Antioxidant Role of Taurine and Oyster Mushroom on Kidneys of Male Mice Induced by Paraquat Herbicide

Endang Linirin Widiastuti^{1, a)}, Endang Nurcahyani¹,
and Bayu Putra Danan Jaya²

¹*Department of Biology, Faculty of Mathematics and Science, University of Lampung, Lampung, Indonesia.*

²*Faculty of Medical Science, University of Lampung, Lampung, Indonesia.*

^aCorresponding author: endang.linirin@fmipa.unila.ac.id

Abstract. The study aimed to explore potential antioxidant effects of organic taurine and oyster mushroom (*Pleurotus ostreatus* (Jacq.) P. Kumm) on diets of male mice induced by paraquat herbicide. Thirty male mice were assigned for this study. They were divided into five groups, namely control, oyster mushroom diet, paraquat, paraquat plus oyster mushroom diet, and paraquat plus taurine diet. The concentration of malondialdehyde (MDA), Glutathione, and superoxide dismutase (SOD) was measured, after three weeks animals were intraperitoneally given paraquat twice a week as much as 20 mg · kg⁻¹ BW. Taurine was given 15.6 g · kg⁻¹ BW and the oyster mushroom pellet was given 62.5 g · kg⁻¹ daily. Complete randomized design was applied to these groups and data was analyzed using ANOVA followed by LSD at 5 %. The results indicated that both additions of taurine and oyster mushroom on diets reduced the concentration of MDA for about 15 % and increased the glutathione concentration for about 30 % ($p < 0.05$), while the concentration of SOD did not show any significantly different among groups ($p > 0.05$), even though both taurine and oyster mushroom diets decreased SOD concentration for about 12 %. In conclusion, both taurine and oyster mushroom affected as an antioxidant by reducing the MDA concentration and increasing in glutathione concentration.

Keywords: antioxidants, oxidative damage, oyster mushrooms, ROS, taurine

INTRODUCTION

Many toxic compounds have been used by human for insecticides or herbicides, one of which is paraquat. Paraquat (1,1'-dimethyl-4,4'-bipyridinium dichloride) is high toxic salt for animals and humans. Large quantities of paraquat exposure can cause death, while exposure in small quantities over long period cause permanent damage to various organs, such as lungs, brain, liver, and kidneys [1, 2]. The toxic mechanism of paraquat is based on its ability to increase free radicals, such as superoxide anions. These superoxide anions then lead to a proliferation of ROS (Reactive Oxygen Species) molecules and oxidation of NADPH (Nicotinamide Adenine Dinucleotide Phosphate) which is required for redox reactions in metabolic processes [3, 4]. The ROS formed then will bind to polyunsaturated fatty acids which found abundant in cell membranes, causing oxidative damage to various organs including kidneys [1].

Many studies had been done to prevent the damage by paraquat using antioxidants. They used some antioxidants, such as vitamin C, vitamin E, N-acetylcysteine, and melatonin which was able to prevent the damage caused by paraquats [2, 5, 6]. Beside those antioxidants, some of free amino acids are also used for this antioxidant action, one of which is taurine. Taurine, one of the amino acids containing sulfur groups which is known play in various functions in the body, as an osmoregulator, neuromodulator, detox [7], and act as an insulin-like growth factor in some fried fish [8, 9]. These compounds are found in most of tissue organs but high concentrations in liver [10]. Taurine is known has the ability to protect liver from chemical compounds that cause hepatotoxicity [11, 12, 13]. Presumably, taurine plays a role as an antioxidant by inhibiting ROS production and binding to ROS in the cells [7, 14, 15]. In addition, taurine is also capable of increasing the activity of antioxidant enzymes [16].

Oyster mushroom is one of edible mushrooms that rich in phenolic compounds, such as polyphenols, which is also known to have high antioxidant activity [17, 18]. This mushroom composes of β -glucan with high antioxidant, increases important antioxidant enzymes, such as SOD, catalase, and peroxidase [19]. However,

there is not much study had been done in the use of oyster mushroom combined with taurine as an antioxidant preventing oxidative damage arising from the exposure of paraquat to kidneys. This study then attempted to explore the antioxidant activity of those oyster mushroom and taurine on the kidneys exposed by paraquat with parameters of study were oxidative damage by measuring MDA, glutathione and SOD enzyme levels, and kidney histopathologic changes.

METHODS

Animal Experiments

A total of 30 DDY strains of mice with weight ranging from 30 g to 40 g were used. They were kept in separate cages at room temperature and light cycle: 12 h of light and 12 h of dark. All experimental animals were fed and drunk in *ad libitum*.

Mushroom Preparation

Oyster mushrooms were bought from traditional markets. The fruit body was cut into small pieces and dried using a hot air oven at temperature of 30 °C to 35 °C. The dried mushrooms then were finely crushed and blended. The mushroom powder was put in a closed bottle and stored at room temperature. Oyster mushroom extract was obtained by boiling 2.5 g of mushroom powder in 1 L of boiling aquadest for 15 min. The extract was then filtered and stored at -40 °C.

Experimental Methods

Mice were randomly divided into five groups, i.e.:

- a. Control (C): mice were fed with standard feed without paraquat, taurine and oyster mushrooms.
- b. P1 group: mice given oyster mushroom in feed with dose $62.5 \text{ g} \cdot \text{kg}^{-1}$ of feed and drinking water with dose $2.5 \text{ g} \cdot \text{L}^{-1}$.
- c. P2 group: mice were fed with standard feed and induced with paraquat at doses of $20 \text{ mg} \cdot \text{kg}^{-1}$ BW intraperitoneal, two times weekly for 3 wk.
- d. P3 group: mice were fed with standard feed, induced with paraquat as in group P2 and given taurine with a dose of $15.6 \text{ g} \cdot \text{kg}^{-1}$ BW.
- e. P4 group: mice were given with oyster mushroom as in group P1 and induced paraquat as in group P2.

After 3 wk, the mice were euthanized. As many as 100 mg of kidney tissues, then was homogenized using Tissue Lyser in 1 ml PBS 0.1 M pH 7.4. The homogenate then was centrifuged at 5 000 rpm for 10 min. The supernatant was transferred to another tube and stored at -20 °C.

Oxidative Damage Analysis

MDA levels were measured using a modified test method of thiobarbituric acid (TBA) based on Zainuri and Wanandi [21]. Glutathione levels were examined using a glutathione examination kit based on Syafrudin and Subandrate [20]. SOD enzyme activity was examined using a RansOD inspection kit from Randox in a manner consistent with the manufacturer's recommendations.

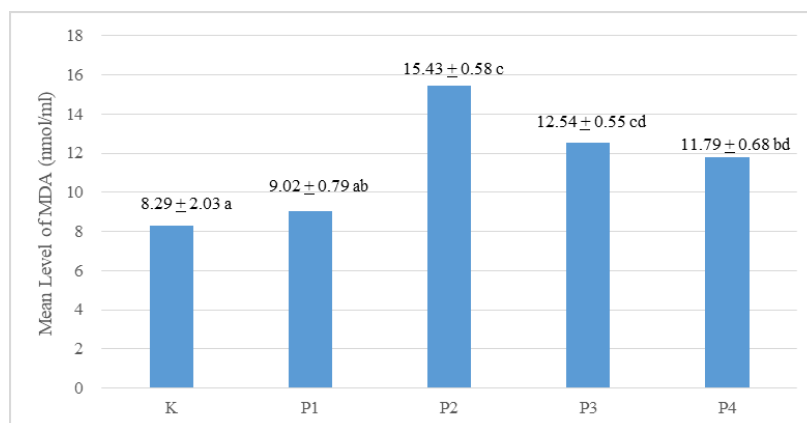
Histopathological Examination

After surgery, the kidneys were fixed using a 10 % formalin buffer; then histopathologic preparations were made with Mayer Hematoxylin stain. The degree of histopathologic differences of the kidney was assessed using the Manja Roenigk scoring [22] with criteria: 0 = normal; 1 = if there is parenchymatous degeneration; 2 = if there is hydropic degeneration and 3 = if there is necrosis.

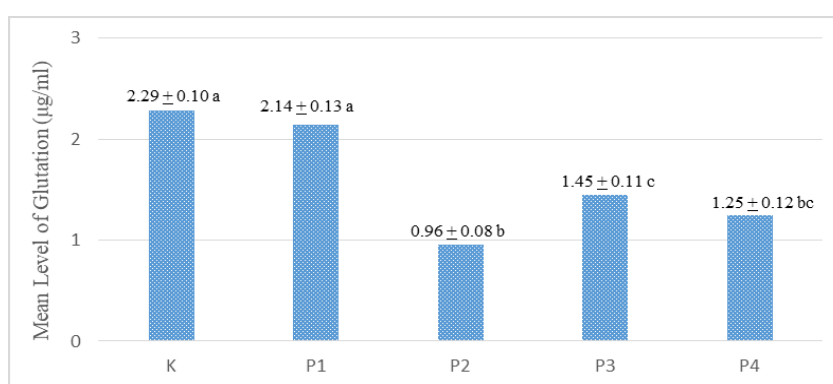
Data analysis

The results of oxidative damage test were tested using one-way ANOVA test followed by Least Significant Difference (LSD). Histopathologic deferences among treatment groups were tested using Kruskal Wallis test followed by Mann Whitney test. All tests were performed at a 95 % confidence level.

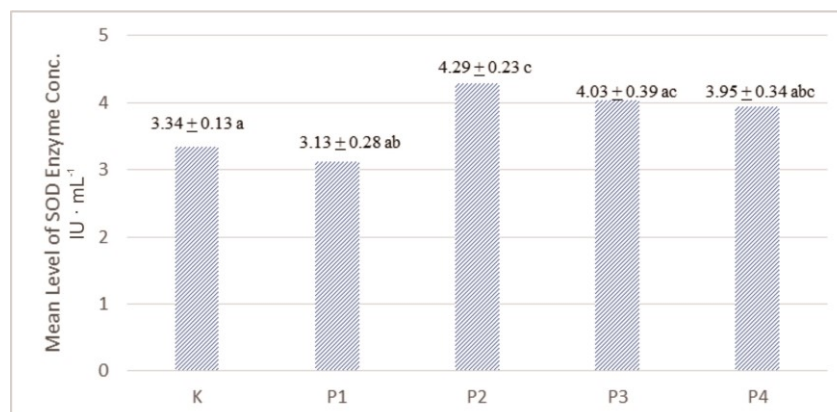
RESULTS



A



B



C

FIGURE 1. Mean of MDA ($\mu\text{mol} \cdot \text{mL}^{-1}$) (A), glutathione ($\mu\text{mol} \cdot \text{mL}^{-1}$) (B), and enzyme SOD ($\text{IU} \cdot \text{mL}^{-1}$) (C), in the kidney of mice with control treatment (K), oyster mushroom (P1), paraquat (P2), paraquat and taurine (P3) as well as paraquat and oyster mushrooms (P4). The mean values followed by the same letter are not significantly different based on the LSD test with $\alpha = 5\%$

Taurine and Oyster Mushrooms Decrease Peroxidation of Fat in Kidneys

The results showed induction of paraquat increased of lipid peroxidation, characterized by elevated liver MDA levels significantly ($p < 0.05$). Administration of taurine and oyster mushrooms, significantly reduce liver MDA levels (Fig. 1).

Taurine and Oyster Mushroom Increases Glutathione Levels

As expected, induction of paraquat shown significant decrease in hepatic glutathione levels ($p < 0.05$). Administration of taurine and oyster mushrooms was also able to increase glutathione levels significantly (Fig. 1).

Taurine and Oyster Mushrooms Reduce Enhancement of SOD Enzyme Levels

Paraquat induction was significantly increased SOD enzyme levels ($p < 0.05$), whereas taurine and oyster mushrooms reduced the elevation of enzyme levels, although they did not show any significant difference ($p > 0.05$) (Fig. 1).

Taurine and Oyster Mushrooms Reduce Histopathology Kidney Damage

Paraquat-induced kidney tubule cells exhibit extensive cytoplasmic swelling and disappearing of nucleus. Edema also showed in Bowman's spatium of glomerulus. Inflammatory cells also identified in the kidney tissues induced by paraquat (Fig. 2). Overall, the mean of histopathologic kidney damage score was presented in Table 1. The administration of taurine and oyster mushrooms, significantly reducing the mean histopathologic damage score ($p < 0.05$).

D ($\text{IU} \cdot \text{mL}^{-1}$) (C) in the kidney of mice with control treatment (K), oyster mushroom (P1), paraquat (P2), paraquat and taurine (P3) as well as paraquat and oyster mushrooms (P4). The mean values followed by the same letter are not significantly different based on the LSD test with $\alpha = 5\%$.

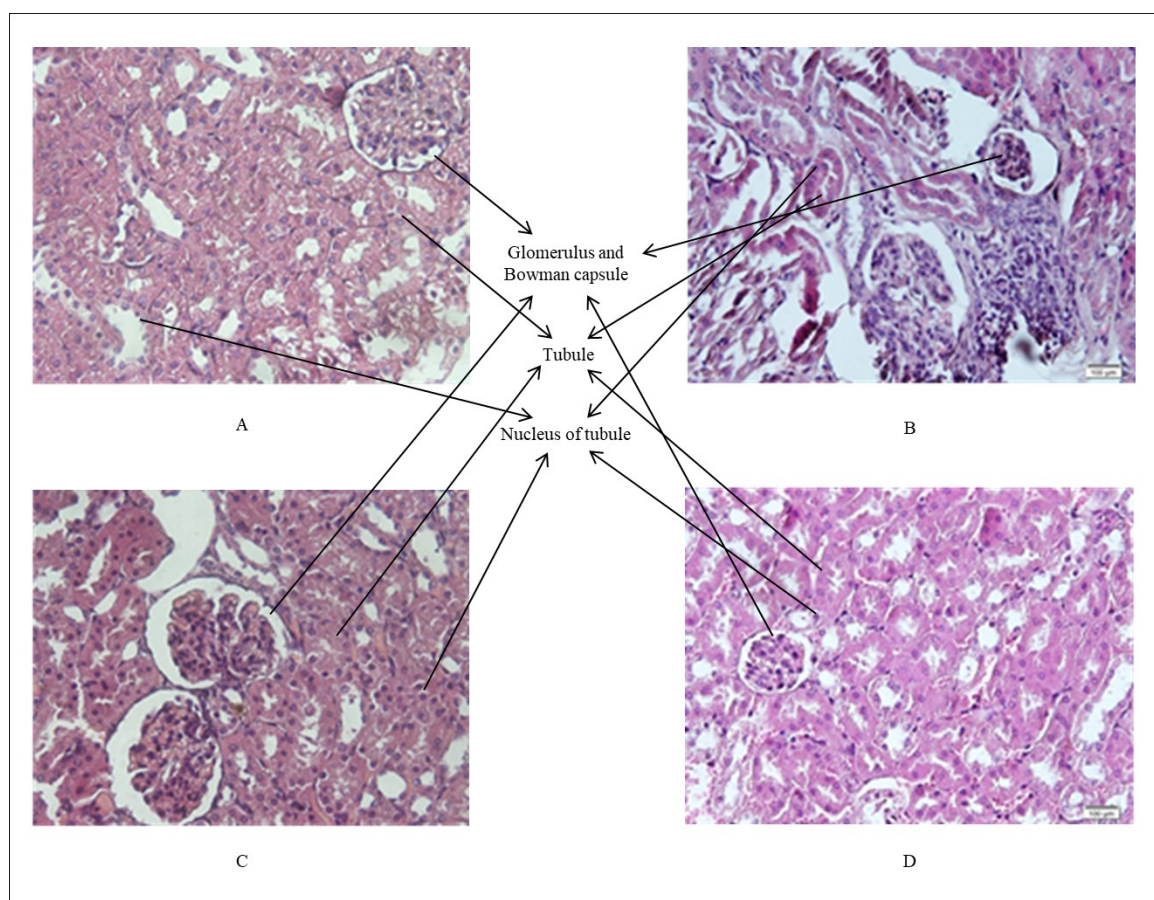


FIGURE 2. Histopathology of the kidney with H&E staining (magnification 400 \times). (A) Kidney controls and oyster mushroom without changes in histopathological features. (B) Paraquat induction ($20 \text{ mg} \cdot \text{kg}^{-1} \text{ BW}$) appears extensive swelling and disappearing of nucleus, edema also showed in Bowman's spatium of glomerulus, as well as inflammatory cells also identified. (C) Paraquat and taurine induction and (D) Induction of paraquat and oyster mushrooms. There appears to be a decrease in cloudy swollen degeneration in hepatocyte cells, but there is still a congestion

TABLE 1. The score of histopathologic kidney damage

Treatment Group (n=6)	Mean ($\bar{X} \pm \text{SEM}$)*
K (-)	0.00 \pm 0.00a
Oyster mushroom	0.00 \pm 0.00 ^a
Paraquat	3.83 \pm 0.17 ^b
Paraquat + Taurine	2.50 \pm 0.34 ^c
Paraquat + O. mushroom	2.33 \pm 0.33 ^c

* The mean values followed by the same letter are not significantly different based on the LSD test with $\alpha = 5\%$

DISCUSSION

Induction of paraquat, in this study, presumably caused an increase in inducing ROS molecules which then lead to tissue damage, shown by the highest score for histopathologic of the kidney (Table 1). This oxidative stress on the kidney tissues damage also indicated by [1]. The kidney tissues damage presumably caused by lipid peroxidation which indicated by an increase in MDA level (Fig. 1 A). This increase in MDA levels is followed by a decrease in glutathione levels (Fig. 1 B) and an excessive increase in SOD enzyme levels (Fig. 1 C). These fluctuation compared to the control group indicate an increase in oxidative damage to the kidney tissues. The presence of oxidative damage promote cellular dysfunction, presumably started by the destruction of membrane cells, and followed by loosing of some nucleus and inflammation of the tubule cells. This occurs since the membrane consisted of polyunsaturated fatty acids which sensitive to the free radicals, such as ROS [23], which was produced by paraquat induction. Therefore, from this study, an increase in MDA levels also could indicate lipid peroxidation of the membrane cells of the kidney tissues leading to tissues damage.

The increase in MDA level (Fig. 1 A) is also indicating high production of ROS molecules, such as O_2^- , H_2O_2 , and O^- [4]. These ROS molecules then react with polyunsaturated fatty acids which formed cellular membrane, producing radical peroxide (ROO^-) with high toxicity and finally it forms MDA. From Fig. 1 A, compared to the control group, the increase in MDA level reaches up to 86.12 % for those group induced by paraquat. Meaning that the occurring reaction keeps running and make a chain reaction, ends up with 86.12 % of MDA concentration. This number is also supported by those [23, 24], in which both stated that the MDA production caused by a chain reaction of radical peroxide might reach 82 %.

Addition of Taurine, a free β amino acid group compound, is likely to reduce oxidative damage in mice induced by paraquat (Fig. 1 A, Table 1). Taurine is able to reduce the MDA production for about 18.72 %. Taurine is known to prevent oxidative damage to various organs [25]. The ability of taurine to prevent hepatoprotective dues to its antioxidant activity, its ability to improve the mitochondrial function by stabilizing the electron transport and preventing the formation of ROS [7] and its ability to bind with ROS in the cells [13–15]. Therefore, we can state that this study indicates that taurine is able to reduce the MDA production by preventing the formation of ROS and reducing the unsaturated lipid peroxidation. Taurine is also able to reduce the MDA production in the kidney of the mice suffered from ischemic leading to ROS production [26].

Addition of taurine on a diet will lead to increase in taurine content of the body. Even though calculation of taurine level has not done, yet by giving taurine as much $15.6 \text{ g} \cdot \text{kg}^{-1} \text{ BW}$ for 3 wk, presumably it is able to increase the taurine level [16] in which they claimed up to 40 % of taurine could be found in the liver after taurine on a diet. It is also expected the taurine content increase in the kidney of the mice giving taurine on a diet after induction of paraquat which leads to respiratory returning from paraquat exposure. Therefore, ATP synthesis rises while superoxide anions production decreases [27]. Once again, the decrease in superoxide anions then will reduce the activity of lipid peroxide which shown by decreasing in MDA levels.

Giving oyster mushroom on diet after paraquat induction seemingly also reduced in kidney tissues damage (Fig. 1 B, Table 1). About 23.59 % of the MDA production and close to 40 % of histopathologic of kidney tissue induced by paraquat is ably reduced by oyster mushroom on a diet. This ability to reduce oxidative stress of the oyster mushroom might due to its ability to donate hydrogen ion from polyphenol contained in the mushroom, in which then the hydrogen ion neutralizes ROS molecules and inhibit the formation of O_2^- and OH^- causing lipid peroxidation [28]. Beside that oyster mushroom also contains *β -glucan* polysaccharide which has antioxidant action [19]. The ability of this oyster mushroom to reduce ROS production and decrease in MDA level caused by diabetic and hypercholesterolemia [29]. Therefore, the free radicals produced by induction of paraquat can be cut off by giving oyster mushroom on a diet [30].

Glutathione levels decreases due to paraquat induction, given oyster mushroom and taurine on diets were able to return the glutathione levels for about 30 % to 51 % (Fig. 1 B). This increase in glutathione level presumably leads to trapping free radicals and preventing oxidation by glutathione as those indicated by [16, 26]. Similarity to it, SOD enzyme level also tends to increase for about 6 % to 8 % due to given taurine and oyster mushroom diets which leads to decrease in ROS (Fig. 1 C).

The percent recovery on histopathology damage (by comparing the histopathologic damage score of paraquat induction with taurine and oyster mushroom diets) for about 35 % to 39 % indicated that both taurine and oyster mushroom are able to prevent further destruction of the tissues caused by ROS. Paraquat caused glomerulus damage indicated by edema in Bowman's spatium which increase in extracellular volume. This increase in extracellular volume was caused by congestion, increase in osmotic pressure and change in membrane permeability [31].

CONCLUSION

This study proves the antioxidant ability of taurine and oyster mushrooms to prevent oxidative damage due to paraquat induction. Both taurine and oyster mushrooms were able to reduce MDA levels for about 15 %, increase glutathione levels for about 30 %, reduce excessive activation of SOD enzymes for about 12 % and reduce kidney damage scores up to 70 %.

ACKNOWLEDGEMENT

The author thanks the Ministry of Research, Technology and Higher Education of the Republic of Indonesia for supporting this research through Graduate Program Grants (PPS) 2017.

REFERENCES

1. M. S. Ortiz, K. M. Forti, E. B. S. Martinez, L. G. M. Munoz, K. Husain, and W. H. Muniz, *Int. J. Sci. Basic Appl. Res.* **26**(1), 26–46 (2016).
2. A. E. Awadalla, *Exp. Toxicol. Pathol.* **64**(5), 431–434 (2010).
3. R. J. Dinis-Oliviera, J. A. Duarte, A. Sánchez-Navarro, F. Remião, M. L. Bastos, and F. Carvalho, *Crit. Rev. Toxicol.* **38**(1), 13–71(2008).
4. R. Franco, R. Sancez-Olea, E. M. Reyes-Reyes, M. I. Panayiotidis, *Mutat. Res.* **674**(1-2), 3–22 (2009).
5. N. Eizadi-Mood, A. M. Sabzghababee, A. Yaraghi, K. Montazeri, M. Golabi, A. Sharifian, *et al.*, *Trop. J. Pharm. Res.* **10**(1), 27–31 (2011).
6. J. M. Moon and B. J. Chun, *Hum. Exp. Toxicol* **30**(8), 844–850 (2010).
7. H. Ripps and W. Shen. *Mol. Vis.* **18**, 2673–2686 (2012).
8. E. L. Widiastuti, N. Nukmal, M. Kanedi, and S. Saputra, “Taurine effects on growth and gona maturation in cobia (*Rachycentron canadum*),” in *International Conference on Biological Science Faculty of Biology Universitas Gadjah Mada 2011 (ICBS BIO-UGM 2011)*, Proceeding Advances in Biological Sciences, edited by Y. A. Purwestri *et al.* (Faculty of Biology, Universitas Gadjah Mada, Yogyakarta, Indonesia, 2011), pp. 315–320.
9. E. L. Widiastuti, M. Kanedi, and N. Nurcahyani, “Early study: The effect of taurine on growth of gourami (*Osprhonemus goramy*) and tilapia (*Oreochromis niloticus*) juveniles,” in *International Conference on Biological Science (ICBS)-2013*, Knowledge-E Life Sciences, edited by R. H. Setyobudi *et al.* (Knowledge E, Dubai, 2015), pp. 336–341.
10. T. M. Batista, R. A. Ribeiro, P. M. R. da Silva, R. L. Camargo, P. C. B. Lollo, A. C. Boschero, *et al.*, *Mol. Nutr. Food Res.* **57**(3), 423–434 (2012).
11. R. Heidari, H. Babaei, and M. A. Eghbal. *Arh. Hig. Rada Toksikol.* **64**, 201–210 (2013).
12. Y. Liao, X. Lu, C. Lu, G. Li, Y. Jin, and H. Tang, *Pharmacol. Res.* **57**(2), 125–131 (2008).
13. H. Tabassum, H. Rehman, B. D. Banerjee, S. Raisuddin, and S. Parvez, *Clin. Chim. Acta* **370**(1–2), 129–136 (2006).
14. S. Ozden, B. Catalgo, S. Gezginci-Oktayoglu, A. Karatug, S. Bolken, and B. Alpertunga, *Toxicol. Ind. Health* **29**(1), 60–71 (2012).
15. Z. Yildirim and N. Kilic, *Int. J. Gerontol.* **5**(3), 166–170 (2011).
16. Z. Zhang, D. Liu, B. Yi, Z. Liao, L. Tang, D. Yin, *et al.*, *Mol. Med. Rep.* **10**(5), 2255–2262 (2014).
17. B. A. Iwalokun, U. A. Usen, A. A. Otunba, and D. K. Olukoya, *Afr. J. Biotechnol.* **6**(15), 1732–1739 (2007).
18. S. Neelam and S. Singh, *Int. J. Pharm. Bio. Sci* **4**(3): 396–400 (2013).
19. Y. Patel, R. Naraian, and V. K. Singh, *World Journal of Fungal and Plant Biology* **3**(1), 01–12 (2012).
20. Syafrudin and Subrandate, *Jurnal Kedokteran dan Kesehatan* **2**(3), 277–281 (2015). [Bahasa Indonesia].
21. M. Zainuri and S.I. Wanandi, *Media Litbang Kesehatan* **22**(2), 87–92 (2012).
22. R Ramachandran and S. Kakar, *J. Clin. Pathol.* **62**(6), 481–492 (2009).
23. A.J. Marciniak, J. Brzeszczynska, K. Gwozdzinski, and A. Jeiger, *Biol. Sport.* **26**(3), 197–213 (2009).
24. M. Valko, D. Leibfritz, J. Moncol, M. T. Cronin, M. Mazur, and J. Telser, *Int. J. Biochem. Cell Biol.* **39**(1), 44–48 (2007).

25. G. Wang, W. Li, X. H. Lu, X. Zhao, and L. Xu, *Croat. Med. J.* **54**(2), 171–179 (2013).
26. G. Guz, E. Oz, N. Lortlar, N. N. Ulusu, N. Nurlu, B. Demirogullari, *et al.*, *Amino Acid* **32**(3), 405–411 (2007).
27. C. J. Jong, J. Azuma, and S. Schaffer. *Amino Acid* **42**(6), 2223–2232 (2012).
28. H. Lin, J. Chen, F. Chou, and C. Wang, *Br. J. Pharmacol.* **162**(1), 237–254 (2011).
29. R. Anandhi, T. Annadurai, T. S. Anitha, A. R. Muralidharan, K. Najmunnisha, V. Nachiappan, *et al.*, *J. Physiol. Biochem.* **69**(2), 313–323 (2013).
30. V. Singh, D. Vyas, and P. S. I. A. Rajshree, *World Journal of Pharmacy and Pharmaceutical Sciences* **4**(05), 1230–1246 (2015).
31. M. S. Kasban, I. Windarti, D. S. Liantari, and S. Susianti, *Jurnal Kedokteran Brawijaya* **29**(1), 43–46 (2016). [Bahasa Indonesia].