

## PAPER NAME

**Antidiabetic Potency of Jeruju - Widiastuti\_2021\_J.\_Phys.\_Conf.\_Ser.\_1751\_012052.pdf**

## AUTHOR

**Endang L Widiatuti**

## WORD COUNT

**4009 Words**

## CHARACTER COUNT

**21598 Characters**

## PAGE COUNT

**10 Pages**

## FILE SIZE

**905.6KB**

## SUBMISSION DATE

**Sep 25, 2022 7:58 PM GMT+7**

## REPORT DATE

**Sep 25, 2022 7:58 PM GMT+7**

### ● 12% Overall Similarity

The combined total of all matches, including overlapping sources, for each database.

- 8% Internet database
- 7% Publications database
- Crossref database
- Crossref Posted Content database
- 4% Submitted Works database

### ● Excluded from Similarity Report

- Bibliographic material
- Manually excluded sources
- Manually excluded text blocks

PAPER • OPEN ACCESS

## Antidiabetic Potency of Jeruju (*Acanthus ilicifolius* L.) Ethanol Extract and Taurine on Histopathological Response of Mice Kidney (*Mus musculus* L.) Induced by Alloxan

To cite this article: E L Widiastuti *et al* 2021 *J. Phys.: Conf. Ser.* **1751** 012052

12 [View the article online](#) for updates and enhancements.

### You may also like

- [Artemia sp. enrichment with vitamin C and taurine to support growth and survival rate of vaname \(\*Litopenaeus vannamei\*\) larvae: early study](#)  
Thia Monica, Supono and Endang Linirin Widiastuti
- 7 [Selective Polishing of Amorphous Silicon Carbonitride \(a-SiCN\) Films Over Silicon Dioxide and Silicon Nitride Films for Hardmask Applications](#)  
Akshay Gowda, Sridevi Alety, Charith K. Ranaweera *et al.*
- [Taurine Intakes Increase Superoxide Dismutase Activity in Knee Osteoarthritis](#)  
A A E W Saraswati, D Sunardi, A M T Lubis *et al.*



The Electrochemical Society  
Advancing solid state & electrochemical science & technology

## 242nd ECS Meeting

Oct 9 – 13, 2022 • Atlanta, GA, US

Presenting more than 2,400  
technical abstracts in 50 symposia



**ECS Plenary Lecture  
featuring  
M. Stanley Whittingham,**  
Binghamton University  
Nobel Laureate –  
2019 Nobel Prize in Chemistry



**Register now!**



# Antidiabetic Potency of Jeruju (*Acanthus ilicifolius* L.) Ethanol Extract and Taurine on Histopathological Response of Mice Kidney (*Mus musculus* L.) Induced by Alloxan

E L Widiastuti<sup>\*1,2</sup>, B K Ardiansyah<sup>1</sup>, N Nurcahyani<sup>1</sup>, A Silvina<sup>1</sup>

<sup>1</sup> Department of Biology, Faculty of Mathematics and Science, University of Lampung,

<sup>2</sup> The Center of Coastal and Marine Studies, University of Lampung

Jl. Prof. Soemantri Brojonegoro No. 1. Gedong Meneng, Rajabasa, Bandar Lampung. 35141

\*Corresponding Author: [elwidi@yahoo.com](mailto:elwidi@yahoo.com)/[endang.linirin@fmipa.unila.ac.id](mailto:endang.linirin@fmipa.unila.ac.id)

**Abstract.** Diabetes arises due to interference with the work of the pancreas in secreting the hormone insulin. The disease can cause a decrease in body immunity and complications of various vital organs such as the kidneys. Jeruju (*Acanthus ilicifolius* L.) leaf and taurine is reported to have antioxidant activity that is potential as antidiabetic agents. The purpose of this study was to determine the effect of jeruju and taurine on blood glucose levels and the ability to regenerate kidney organs damaged by alloxan induction. This study used a Completely Randomized Design with 5 treatment groups and 5 replications each. K1 group as a negative control (no treatment given), K2 group as a positive control (only induced by alloxan), group P1 induced alloxan and given 100% ethanol extract of jeruju leaf 22.4 mg/bw/day, group P2 induced alloxan and given alloxan 50% ethanol extract of jeruju leaf dose 22.4 mg/bw/day, group P3 was induced by alloxan and given a taurine dose of 15.6 mg/bw/day for 14 days. Data were analyzed by ANOVA followed by LSD at 5% of significant level. The results showed that the administration of jeruju extract and taurine affected the bodyweight of mice, and was significantly able to reduce blood glucose levels by 69.39% (P1), 67.06% (P2), 73.77% (P3), able to repair kidney damage after alloxan induction.

## 1. Introduction

Exposure to excessive free radicals cause oxidative stress where an imbalance occurs between oxidants and antioxidants in the body. The inability of the body to ward off free radicals causes the emergence of various chronic diseases including diabetes which is characterized by high levels of glucose in the blood [1]. Diabetes occurs due to metabolic disorders of the pancreas so that it cannot produce enough insulin or the body cannot use the insulin that is produced effectively. When insulin secretion is disrupted, the energy that should be produced from the glucose overhaul is not formed. As a result, high glucose levels due to a build-up of glucose in the blood [2].

Exposure to free radicals that causes diabetes could be prevented by herbal medicines that contain antioxidants. One of the plants that have potential as antidiabetic agents is jeruju (local name) (*Acanthus ilicifolius* L.) or holy mangrove which contains various bioactive compounds such as flavonoids, saponins, tannins, alkaloids, and steroids [3]. In addition to jeruju, the organic compound



Content from this work may be used under the terms of the [Creative Commons Attribution 3.0 licence](https://creativecommons.org/licenses/by/3.0/). Any further distribution of this work must maintain attribution to the author(s) and the title of the work, journal citation and DOI.

taurine is reported to be able to overcome diabetes through its antioxidant mechanisms and can improve the pancreas in secreting insulin [4,5]. Therefore, in this study we would like to explore any potential used of ethanolic jeruju leaf extraction and taurine.

## 2. Methods

### 2.1 Preparation of Jeruju Extract

250 grams of dried Jeruju leaf powder was macerated using 100% pro analysis ethanol solvent and 50% technical ethanol as much as 2.5 liters for 24 hours (ratio 1:10). The filtrate was filtered and concentrated using a rotary evaporator at 50 °C until a thick extract was obtained then made it in paste form by putting into the oven at 50 °C for several hours. Prior given to treated animal, the extract was dissolved by using 1% CMC, while taurine in the form of powder was dissolved using warm distilled water slowly.

To indicate bioactive compound, phytochemical procedures was applied as follows.

| Bioactive Compounds | Treatment   | Indicator                            |
|---------------------|---|--------------------------------------|
| Saponin             | 0.5 ml sample + 5 ml distilled water and shaken for 30 seconds  | Foam formed                          |
| Tannin              | 1 ml sample + drops of FeCl <sub>3</sub> solution   | Bluish black color                   |
| Steroids            | 0.5 ml sample + 0.5 ml glacial acetic acid + 0.5 ml H <sub>2</sub> SO <sub>4</sub>  | Blue or turquoise                    |
| Terpenoids          | 0.5 ml sample + 0.5 ml glacial acetic acid + 0.5 ml H <sub>2</sub> SO <sub>4</sub>  | Orange, red or yellow                |
| Alkaloids           | 0.5 ml sample + 5 drops of chloroform + 5 drops of Meyer reagent (1 g KI dissolved in 20 ml distilled water and added 0.271 g HgCl <sub>2</sub> ) | Brownish white color                 |
| Flavonoids          | 0.5 ml sample + 0.5 g Mg powder + 5 ml concentrated HCl   | Red or yellow color and foams formed |

### 2.2 Diabetes Testing and Provision of Test Materials

Some Diabetes-conditioned mice were preceded by fasting for ± 6-8 hours, then measured blood glucose levels and initial body weight before treatment. Furthermore, alloxan-induced mice subcutaneously at the nape of the neck with a dose of 160 mg/kg bw which was previously dissolved using 0.3 ml aqua-pro injection. Mice were categorized as diabetes if fasting blood glucose levels reached > 200 mg/dL [6]. After positively experiencing an increase in blood glucose levels, groups of mice were given the extract of jeruju leaves of jeruju leaves with a dose of 22.4 mg/bw/day and a taurine dose of 15.6 mg /bw/day orally for 14 days.

### 2.3 Experimental Design

Twenty-five male mice (*Mus musculus* L.) from Veterinary Region III of Lampung Province (BPPV) Indonesia were used in this study. They were in 3-4 months old with body weight ranges of 30-40 grams. They randomized put in five different treatment groups: Control group (K1) with no alloxan induction nor jeruru extract/taurine, Positive control group (K2) were given alloxan induction to experience increase in blood glucose level, other three groups prior alloxan induction were Treatment 1 group (P1) given jeruju 100% Et extraction, Treatment 2 group (P2) given jeruju 50% Et extraction and Treatment 3 group (P3) given taurine.

### 2.4 Kidney Histopathology Preparation and Scoring of Kidney Damage

Histopathological preparations consisted of several stages including fixation, dehydration, embedding, cutting, staining (Hematoxylin-Eosin staining), and mounting stages. Renal damage scoring was an accumulation of glomerulus damage scores and tubular scoring in 5 visual fields. Glomerular damage score ie, normal (0); inflammatory cell infiltration (1); edema spatium bowman (2); and necrosis (3). While the score of damage to the renal tubules is, normal (0); inflammatory cell infiltration (1); congestion (2); swelling of the tubular epithelium (3); and necrosis (4) [7, 8].

### 2.5 Data Analysis

Glucose levels data, bodyweight of mice, kidney wet weight were analyzed with One Way ANOVA and LSD (Least Significant Difference) test at 5 % significance level. While scoring kidney damage was analyzed by the Kruskal-Wallis Test and Wilcoxon-Mann-Whitney test at 5% level.

## 3. Result And Discussion

3.1 Phytochemical result of jeruju extraction can be seen in Table 1 as follow.

Table 1. Phytochemical Test Results of Jeruju Leaf Extract with Ethanol

| Compound   | Jeruju Leaves Ethanol Extract |             |
|------------|-------------------------------|-------------|
|            | 100% Ethanol                  | 50% Ethanol |
| Flavonoids | ++                            | +           |
| Alkaloids  | +                             | +           |
| Saponin    | +                             | +           |
| Steroids   | -                             | -           |
| Terpenoids | -                             | -           |
| Tannin     | +                             | +           |

Note : (+) = contain test compounds  
(-) = not contain test compounds

Based on the results of phytochemical tests, extracts of jeruju (*Acanthus ilicifolius* L.) leaf, whether extracted using 100% ethanol solvent or 50% ethanol, contained of flavonoids, alkaloids, saponins and tannins. These compounds were known for their antioxidant effect that counteract free radicals released by cell damage and triggered various diseases such as diabetes [9, 10].

### 3.2 Mice Weight Average

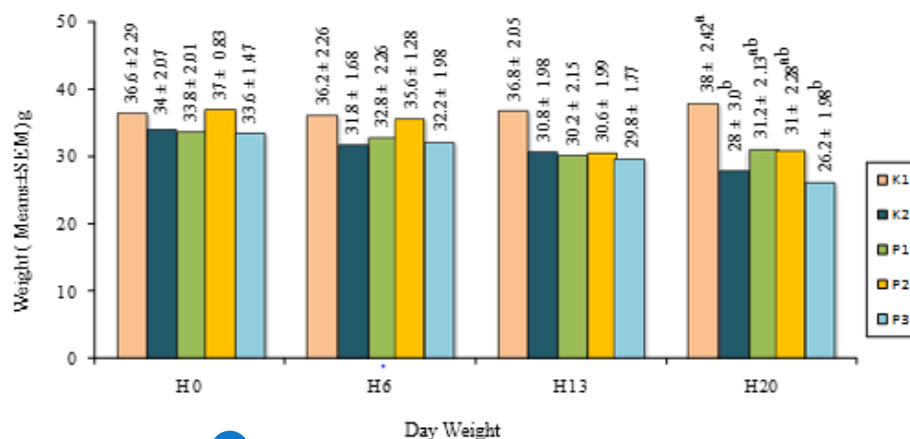


Figure 1. Average body weight of mice throughout the treatment group (different superscript values showed a significant difference  $p \leq 0.05$ ).

Alloxan induction caused weight loss in groups K2, P1, P2, and P3. It is known that alloxan could damage the structure of the pancreas so that insulin secretion and metabolic rate in the body was disrupted. The administration of ethanolic jeruju leaf extraction was able to increase the average body weight of mice indicated in group P1 and P2 on the 20th day observation, although it was not yet fully restored as the initial body weight. Antioxidant compounds such as flavonoids, tannins, alkaloids, saponins presumably could improve the pancreas in secreting insulin so that the process of glucose metabolism in the body could be restored and used to synthesize other biomolecules resulting in weight gain. On the other hand, Taurine in this study was not able to increase the bodyweight after alloxan induction.

### 3.3 Changes in Mean Fasting Blood Glucose of Mice

Table 2. Mean Fasting Blood Glucose of Mice (Mean  $\pm$  SEM, mg/dL)

| Treatment Group | Day-0           | Day-6                         | Day-13                         | Day-20                        |
|-----------------|-----------------|-------------------------------|--------------------------------|-------------------------------|
| 1               | 79.4 $\pm$ 7.2  | 74.6 $\pm$ 4.6 <sup>a</sup>   | 70.0 $\pm$ 7.2 <sup>a</sup>    | 93.0 $\pm$ 6.5 <sup>a</sup>   |
| K2              | 96.0 $\pm$ 10.0 | 327.2 $\pm$ 34.6 <sup>b</sup> | 243.0 $\pm$ 38.7 <sup>b</sup>  | 220.0 $\pm$ 48.7 <sup>b</sup> |
| P1              | 80.6 $\pm$ 9.6  | 319.4 $\pm$ 38.3 <sup>b</sup> | 222.4 $\pm$ 72.7 <sup>b</sup>  | 101.2 $\pm$ 21.2 <sup>a</sup> |
| P2              | 90.6 $\pm$ 8.2  | 334.8 $\pm$ 59.3 <sup>b</sup> | 110.6 $\pm$ 14.1 <sup>ab</sup> | 110.2 $\pm$ 23.1 <sup>a</sup> |
| P3              | 83.0 $\pm$ 11.6 | 305.0 $\pm$ 49.5 <sup>b</sup> | 182.6 $\pm$ 74.4 <sup>ab</sup> | 80.0 $\pm$ 10.9 <sup>a</sup>  |

Note: different superscript values showed significant difference ( $p \leq 0.05$ ).

On the 6th day, all treatment groups induced by alloxan experienced an increase in blood glucose levels above 300 mg/dL. Alloxan caused an increase in blood glucose since it has cytotoxic effect and caused damage to insulin-producing pancreatic  $\beta$  cells through the formation of free radicals and oxidative stress.

Treatment with Et extract of jeruju leaf and taurine could reduce blood glucose levels in P1, P2, and P3 until reaching normal blood glucose levels. The decrease of blood glucose level could be due to the high antioxidant content in the extract and taurine. Ethanol extract of Jeruju (*Acanthus ilicifolius* L.) leaf reduced blood glucose levels presumably through intra-pancreatic and extra-pancreatic mechanisms. The intra-pancreatic mechanism worked with active compounds of alkaloids and flavonoids that were able to regenerate the damaged pancreatic  $\beta$  cells so as to increase insulin secretion through sympathetic nerve stimulation and protect damaged nerves pancreatic cells from free radicals [11, 12]. In the extra-pancreatic mechanism, alkaloids and saponins decrease blood glucose by inhibiting glucose absorption in the intestine so that glucose entering the bloodstream decreases, stimulating glycogen synthesis and inhibiting the enzyme  $\alpha$ -glucosidase.

The treatment with taurine dose of 15.6 mg/bw/day showed a decrease in the highest glucose level of 73.77%. Taurine was thought to play a role in the tolerance of blood glucose which reacted in metabolic processes. High antioxidant activity of taurine presumably could suppress free radicals from alloxan so as to reduce blood glucose levels. Other studies also indicated that administration of taurine was able to reduce the blood glucose of alloxan-induced mice [3,13,14]. According to Carneiro taurine was able to control glucose homeostasis through the regulation of gene expression that was useful in insulin secretion and increases peripheral insulin sensitivity [15]. Taurine also was able to modify the factors that cause susceptibility to toxic chemicals and could protect the body from toxicity due to the induction of carbon tetrachloride [16].

### 3.4 Average Weight of Mice Wet Kidney Organs

Subcutaneous alloxan induction caused a significant reduction in renal wet weight at K2, P1, P2, and P3 as shown in Figure 2.

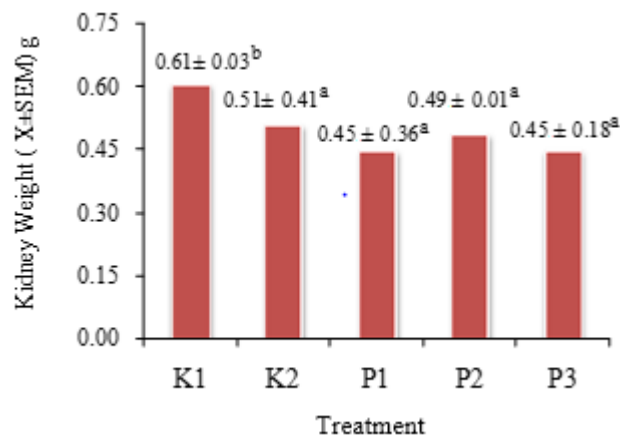


Figure 2. The average weight of mice wet kidney

Reduction in kidney wet weight was thought to be due to the toxic effects of alloxan which resulted in changing in the structure of the kidney organs. The kidney becomes one of the target organs of toxic compounds because it acts as a place of excretion through which some blood passes and functions to filter out harmful substances. In line with this, the antioxidants contained in Et jeruju leaf and taurine were thought to be able to fight alloxan toxic compounds. It was showed that antioxidant compounds such as saponins can affect the ratio or index of organs that can act as nephroprotective [17,18].

### 3.5 Mean Damage Score and Description of Mice Kidney Histopathology

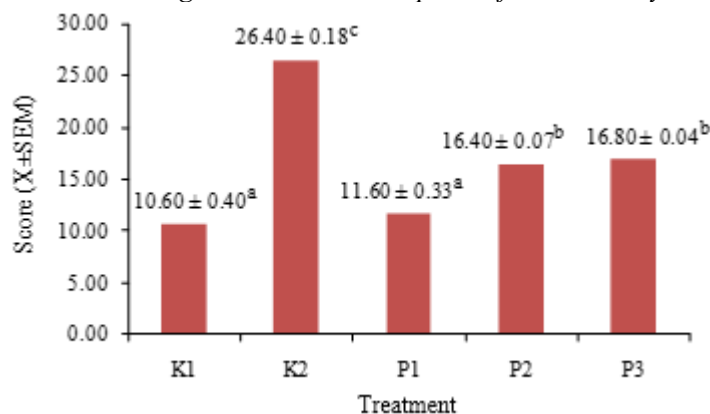


Figure 3. Histopathological damage score of mice kidney

The alloxan-induced group (K2) had the highest damage score of  $26.40 \pm 0.18$  and was significantly different from the entire treatment group ( $p < 0.05$ ). Histopathological scoring results described the level of kidney organ damage in each treatment. The damage score was an accumulation of glomerular observation score and renal tubular observation score as seen in Figure 3.



### 3.6 Comparison of Mice Kidney Histopathology

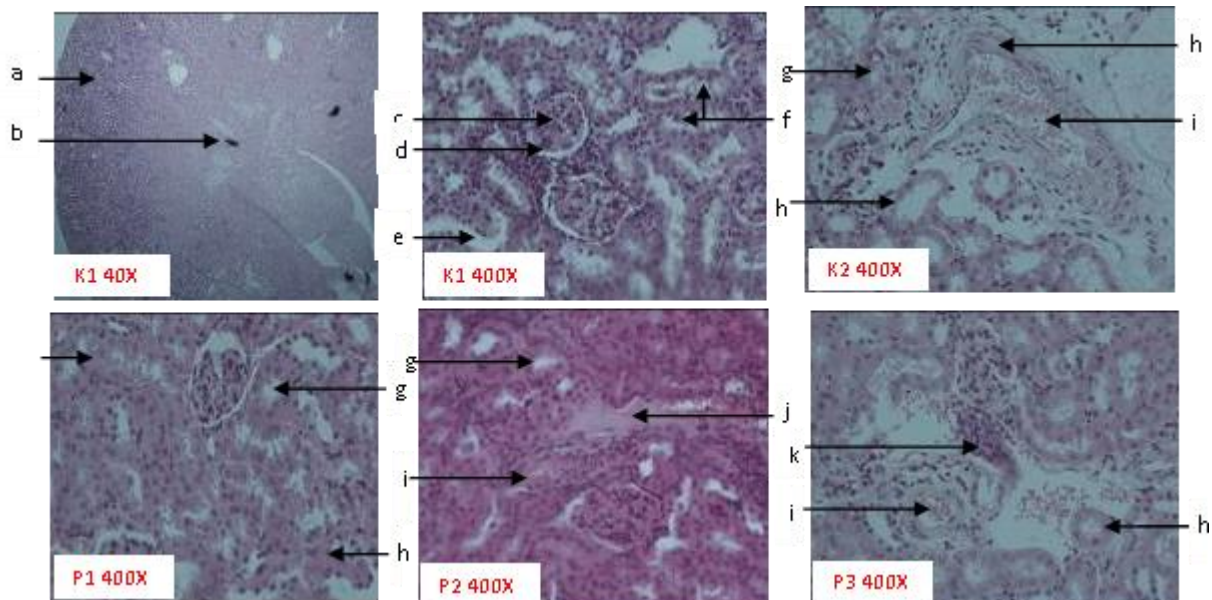


Figure 4. Comparison of renal histopathology picture of all treatment groups (Hematoxylin-Eosin staining). Note: a) cortex, (b) medulla, (c) normal glomerulus, (d) Bowman capsule, (e) proximal tubule, (f) distal tubule, (g) swelling of tubular epithelium, (h) necrosis, (i) congestion, (j) edema, (k) infiltration of inflammatory cells

K1 group had the lowest level of damage and could be categorized as the best or normal compared to the other treatment groups. The structure of the glomerulus, Bowman's capsule, proximal tubule, and distal tubule can be observed clearly.

In the K2 group had the worst damage compared to the other treatment groups. It was believed that high blood glucose levels caused kidney structure to change so that its function was disrupted. In the K2 group, the damage was seen in the form of proximal tubular epithelial cell narrowing, inflammation cell infiltration, congestion, and necrosis in both the tubules and glomerulus. Swelling of the tubular epithelium was thought to be due to bleeding, injury to the tubules, and the cell nucleus that begins to fade causing the tubules to narrow. Necrosis or death of glomerular and tubular cells was caused due to interference and exposure to toxic compounds that occur continuously. The high blood glucose levels caused disruption of homeostasis which was characterized by the release of calcium ions from the mitochondria and the beginning of cell death (necrosis) [19]. Cells that experience necrosis will release various mediators which become the beginning of the inflammatory process and attract the appearance of inflammatory cells. Inflammation of inflammatory cells arise as a response of blood vessels to damaged glomerular and tubular cells. Congestion (blood weir) that occurs in the kidneys was characterized by the presence of blood cells that meet the lumen in the blood vessels. Congestion arises because of increased blood volume due to the dilation of small blood vessels or capillaries [20]. Congestion that occurs continuously is directly proportional to the increase in extracellular and extravascular fluid volume accompanied by fluid retention in the tissues and serous cavities that are the cause of edema.

In group P1, the glomerulus looked normal and no swelling occur. Cells in the proximal and distal tubules appear to have less necrosis compared to the K2 group although there was still some damage such as edema, congestion, and narrowing of the tubular lumen. The improvement in group P1 was thought to be due to the antioxidant activity contained in 100% ethanol extracts of jeruju leaf. These



antioxidants play an important role in repairing cells due to exposure to free radicals. Beside, flavonoid and alkaloid compounds in jeruju have antioxidant activity as suppressants for free radicals and were able to repair the pancreatic and liver organs due to toxic alloxan compounds [3].

In the P2 group, the glomerulus looked normal and there was no swelling, the congestion was lighter than in the K2 group, although infiltration of inflammatory cells was still seen, and the narrowing of the tubular epithelium was seen. The rate of improvement in the K2 group was lower than in the P1 group although both of them used jeruju leaf extract. The difference in the rate of kidney repair was thought to be due to differences in the solvent used in the maceration process. Antioxidant compounds such as flavonoids are polar compounds and will be attracted to extractions with polar solvents as well as to get maximum results [21]. Polarity which is more suitable and compatible with the bioactive components contained in jeruju leaf so that it can attract more secondary metabolites of jeruju leaf compared to those used 50% ethanol in P2 group.

In the P3 group, the proximal and distal tubule structures looked normal although some cells still had necrosis, congestion, tubular epithelial narrowing, and inflammatory cell infiltration. P3 improvement rates were still below P1 and P2. The taurine compound administered orally was thought to have good enough antioxidant activity so that it reduced free radicals from alloxan which caused damage to the kidneys. Taurine acts as an antioxidant by taking local and systemic Reactive Oxygen Species (ROS) free radicals, preventing lipid peroxide by stabilizing lipids in cell membranes and being effective in binding free radicals before reacting with cell molecular components. The administration of taurine can reduce tissue injury, apoptosis, and necrosis in kidney epithelial cells that are ischemic due to high ROS levels from free radicals [22,23,24].

#### 4. Conclusion

Ethanol extraction of Jeruju leaf with dose of 22.4 mg/bw/day and taurine with of dose 15.6 mg/bw/day for 14 days can reduce blood glucose levels, able to improve kidney damage, and affect the weight body of mice (*Mus musculus* L.) induced by alloxan.

#### 5. Reference

- [1] Gayathri GA and Gayathri M. 2014. Preliminary Qualitative Phytochemical Screening and In Vitro Hypoglycemic Potential Of *Acanthus ilicifolius* and *Evolvulus emerginatus*. Int J Pharm Pharm Sci, Vol 6, Issue 6, 362-365.
- [2] Soegondo S. 2011. Diagnosis dan Klasifikasi Diabetes Melitus Terkini dalam: Soegondo, S., Soewondo, P., Subekti, I., Editor. Penatalaksanaan Diabetes Melitus Terpadu bagi dokter maupun edukator diabetes. Fakultas Kedokteran Universitas Indonesia. Jakarta
- [3] Nurfitri WA, Widiastuti EL, dan Nurcahyani E. 2018. Efek Ekstrak Metanol Daun Jeruju (*Acanthus Ilicifolius* L.) Serta Buah Jeruju Dan Taurin Dalam Menurunkan Kadar Glukosa Darah Dan Kolesterol Serta Fertilitas Mencit Jantan (*Mus musculus*) Yang Diinduksi Aloksan. (Prosiding Seminar Nasional Tumbuhan Obat Indonesia ke-55 Universitas Tidar dan Kelompok Kerja Nasional Tumbuhan Obat Indonesia).
- [4] Tasci I, Mas MR, Vural SA, Deveci S, Comert BG, Alcigir N, Mas C, Akay M, Bozdayi C, Yurdaydin H, Bozkaya O, Uzunalimoglu AT, Isik HM and Said. 2007. Pegylated interferon-alpha plus taurine in treatment of rat liver fibrosis. World Journal of Gastroenterology 13: 3237-3244.
- [5] Puerta FJ, Arrieta JA, Balsa JJ, Botella-Carretero, Zamarron and Vazquez C. 2010. Taurine and glikose metabolism : A review 25 (6) 910-919.
- [6] Maiyah AT, Widiastuti EL, Umar S. 2016. Ameliorative effects of *Costus speciosus* on

- biochemical and histopathological changes in alloxan-induced diabetic mice. *Science Letters* Vol. 4. Issue 2. Pp. 140-146.
- [7] Dewi AK, Rahardjo IB, Gunawan A. 2014. Perbedaan Jumlah Limfosit Daerah Pals (Periarterial Lymphoid Sheat) Antara Mencit Sehat Dan Mencit Diabetes. *Majalah Biomorfologi*. Volume 27 No. 1.
- [8] Muhartono, Windarti, I., Diah, S. L., Susianti. 2016. Risiko Herbisida Paraquat Diklorida terhadap Ginjal Tikus Putih Spraque Dawley. *Jurnal Kedokteran Brawijaya*. Vol. 29, No.1.
- [9] Khajure PV, Rathod, JL. 2010. Antimicrobial Activity of Extracts of *Achantus ilicifolius* Extracted from the Mangroves of Karwar Coast Karnataka. *Recent Research in Science and Technol*. Vol 2 No.6, hal 98-99.
- [10] Fithriani D. 2009. Potensi Antioksidan *Caulerpa racemosa* Di perairan Teluk Harun Lampung. (Tesis). Institut Pertanian Bogor. Bogor.
- [11] Arjadi F dan Mustofa. 2017. Ektrak Daging Buah Mahkota Dewa *Phaleria macrocarp* (scheff.) Boer Meregenerasi Sel Pulau Langerhans Pada Tikus Putih Diabetes. *Jurnal Ilmiah Biologi Biogenesis*. Vol 5, No. 1 : 27-33.
- [12] Aziz MTA, Elasmr, MF, Rezaq AM, Mahfouz SM, Wassef MA, Fouad HH, Ahmed HH and Taha F. 2013. The effect of a novel curcumin derivative on pancreatic islet regeneration in experimental type-1 diabetes in rats (long term study). *Diabetology & Metabolic Syndrome*, Vol 5: 75.
- [13] Widiastuti EL, Sutyarso, Susanto GN, Rudini M and Kanedi M. 2017. Ameliorative Properties of Crude Diosgenin from *Costus speciosus* and Taurine on Testicular Disorders in Alloxan-Induced Diabetic Mice. *Biomedical & Pharmacology Journal*. Vol. 10(1),09-17.
- [14] Yohannes, Widiastuti EL, dan Nurcahyani E. 2018. Efek Ekstrak Metanol Makroalga Merah (*Gracillaria* Sp) Makroalga Cokelat (*Padina* Sp.) Dan Taurin Terhadap Kadar Glukosa Darah, Kolesterol Dan Viabilitas Spermatozoa Mencit Jantan (*Mus musculus*) Yang Diinduksi Aloksan. (Prosiding Seminar Nasional Tumbuhan Obat Indonesia ke-55. Universitas Tidar dan Kelompok Kerja Nasional Tumbuhan Obat Indonesia. ISBN: 978-602-53915-9-7).
- [15] Carneiro EM, Latorraca MQ, Araujo E, Beltra M, Oliveras MJ, Navarro M, Berna G, Bedoya FJ, Velloso LA, Soria B, Martin F. 2009. Taurine supplementation modulates glucose homeostasis and islet function. *Journal of Nutritional Biochemistry* 20: 503-511.
- [16] Ripps H and Shen W. 2012. Review: taurine: a very essential amino acid. *Mol Vis*;18:2673–86.
- [17] Debnanth S, Babre N, Manjunath YS, Mallareddy V, Parameshwar P dan Hariprasath K. 2010. Nephroprotective Evaluation of Ethanolic Extract of The Seeds of Papaya and Pumpkin Fruits In Ciplatin-Induced Nephrotoxicity. *Journal of Pharmaceutical Science and Technology*. Vol 2 ( 6).
- [18] Puspitasari D. 2015. Uji Toksisitas Subkronik Ekstrak Air Daun Katuk (*Sauropus Androgynus*) Terhadap Histologi Dan Berat Ginjal Tikus (*Rattus Norvegicus*) Betina. (Skripsi). Jurusan Biologi Fakultas Sains Dan Teknologi Universitas Islam Negeri Maulana Malik Ibrahim Malang.
- [19] Handani AR, Salim MN, Harris A, Budiman H, Zainudin, Sugito. 2015. Pengaruh Pemberian Kacang Panjang (*Vigna unguiculata*) Terhadap Struktur Mikroskopis Ginjal Mencit (*Mus musculus*) yang Diinduksi Aloksan. *Jurnal Medika Veterinaria*. Vol. 9 No. 1. <https://e-journal.unair.ac.id/MBIO/article/viewFile/15991/8620>. diakses 5 Mei 2020
- [20] Kumar V, Abbas AK, Aster JC, Robbins SL. 2005. Robbins Basic Pathology. Philadelphia: Elsevier Saunders.
- [21] Permadi A, Sutanto dan Wardatun. 2015. Perbandingan Metode Ekstraksi Bertingkat Dan Tidak Bertingkat Terhadap Flavonoid Total Herba Ciplukan (*Physalis Angulata* L.) Secara Kolorimetri. *Jurnal Online Mahasiswa Bidang Farmasi*. Vol 1 No. 1. <https://jom.unpak.ac.id/index.php/Farmasi/article/view/706/646>.

- [22] Roselyn AP, Widiastuti EL, Susanto GN, Sutyarso. 2015. Pengaruh Pemberian Taurin terhadap Gambaran Histopatologi Paru Mencit (*Mus musculus*) yang Diinduksi Karsinogen Benzo(a) Pirensecara InVivo. *Jurnal Natur Indonesia* 17(1), 22–32
- [23] Moloney MA, Casey RG, O'Donnell DH, Fitzgerald P, Thompson C, Bouchier-Hayes DJ. 2010. Two Weeks Taurine Supplementation Reverses Endothelial Dysfunction In Young Male Type 1 Diabetics. *Diab Vasc Dis Res* in press.
- [24] Michalk DV, Hoffmann B, Minor T. 2003. Taurine reduces renal ischemia/reperfusion injury in the rat. *Adv Exp Med Biol.* 526:49–56. [PubMed] [Google Scholar].

## ● 12% Overall Similarity

Top sources found in the following databases:

- 8% Internet database
- Crossref database
- 4% Submitted Works database
- 7% Publications database
- Crossref Posted Content database

### TOP SOURCES

The sources with the highest number of matches within the submission. Overlapping sources will not be displayed.

|   |   |     |
|---|---|-----|
| 1 | "Taurine 11", Springer Science and Business Media LLC, 2019             | 1%  |
|   | Crossref  |     |
| 2 | Hongli Ye, Liangliang Tian, Youqiong Cai, Dongmei Huang, Zhaodong S...  | <1% |
|   | Crossref  |     |
| 3 | researchgate.net  | <1% |
|   | Internet  |     |
| 4 | Udayana University on 2018-06-03  | <1% |
|   | Submitted works   |     |
| 5 | Hendri Busman, Reza Pina Lestari, Emantis Rosa, Achmad Arifiyanto. "... | <1% |
|   | Crossref  |     |
| 6 | Eastern Institute of Technology on 2021-08-09                           | <1% |
|   | Submitted works   |     |
| 7 | iopscience.iop.org  | <1% |
|   | Internet  |     |
| 8 | atlantis-press.com  | <1% |
|   | Internet  |     |

|    |  |     |
|----|--|-----|
| 9  | garuda.kemdikbud.go.id   | <1% |
|    | Internet   |     |
| 10 | R R Setiadi, A F M Z Zein, D Nauphar. " Antihyperglycemic effectiveness... | <1% |
|    | Crossref   |     |
| 11 | dokumen.pub  | <1% |
|    | Internet   |     |
| 12 | repository.unair.ac.id   | <1% |
|    | Internet   |     |
| 13 | Calamvale Community College on 2022-07-29                                  | <1% |
|    | Submitted works  |     |
| 14 | Zike He, Kaifei He, Shangzeng Wang. "Traditional Chinese medicine ort...   | <1% |
|    | Crossref   |     |
| 15 | jurnal.ahmar.id  | <1% |
|    | Internet   |     |
| 16 | pubs.rsc.org   | <1% |
|    | Internet   |     |
| 17 | digilib.unila.ac.id  | <1% |
|    | Internet   |     |
| 18 | eresearch.ozyegin.edu.tr   | <1% |
|    | Internet   |     |
| 19 | pdfs.semanticscholar.org   | <1% |
|    | Internet   |     |
| 20 | ijstr.org  | <1% |
|    | Internet   |     |

|    |  |     |
|----|--|-----|
| 21 | <b>edoc.site</b><br>Internet   | <1% |
| 22 | <b>link.springer.com</b><br>Internet   | <1% |
| 23 | <b>semanticscholar.org</b><br>Internet   | <1% |
| 24 | <b>"Taurine 10", Springer Science and Business Media LLC, 2017</b><br>Crossref | <1% |
| 25 | <b>Staffordshire University on 2013-01-09</b><br>Submitted works               | <1% |
| 26 | <b>Udayana University on 2022-07-15</b><br>Submitted works                     | <1% |



## ● Excluded from Similarity Report

- Bibliographic material
- Manually excluded text blocks
- Manually excluded sources

### EXCLUDED SOURCES

**E L Widiastuti, B K Ardiansyah, N Nurcahyani, A Silvinia. "Antidiabetic Potency...** 70%

Crossref

**E L Widiastuti, B K Ardiansyah, N Nurcahyani, A Silvinia. " Antidiabetic Potenc...** 69%

Crossref

**tojqi.net** 5%

Internet

**repository.lppm.unila.ac.id** 2%

Internet

**Hafiludin, S Andayani, H Kartikaningsih, M Firdaus, Mojiono. "Alteration of infl...** 2%

Crossref

**irep.iium.edu.my** 1%

Internet

### EXCLUDED TEXT BLOCKS

**Journal of Physics: Conference SeriesPAPER • OPEN ACCESS**

repository.lppm.unila.ac.id

**Antidiabetic Potency of Jeruju (Acanthus ilicifolius L.)Ethanol Extract and Taurine ...**

E L Widiastuti, B K Ardiansyah, N Nurcahyani, A Silvinia. "Antidiabetic Potency of Jeruju (Acanthus ilicifolius ...

**taurine is reported to be able to overcome diabetes through its antioxidant mecha...**

E L Widiastuti, B K Ardiansyah, N Nurcahyani, A Silvinia. " Antidiabetic Potency of Jeruju ( L.) Ethanol Extract...

**Journal of Physics: Conference Series**IOP Publishing

Eastern Institute of Technology on 2021-08-09

---

**Antidiabetic Potency of Jeruju (*Acanthus ilicifolius***

repository.lppm.unila.ac.id

---

**Artemia sp. enrichment with vitamin C and taurine to support growth and survival ...**

pasca.unila.ac.id

---

**of vaname (*Litopenaeus vannamei*) larvae: early study**Thia Monica, Supono

pasca.unila.ac.id

---

**Histopathological Response of Mice Kidney (Mus**

www.semanticscholar.org

---