

## LEMBAR PENGESAHAN

1. Judul : Ethanol extract of *Bruguiera gymnorrhiza* mangrove leaves and propolis activity on macroscopic healing of cuts in vivo
2. Penulis : **Evi Kurniawaty**, Shina Megaputri, Syazili Mustofa, Soraya Rahmanisa, Kholis A. Audah, Silvia Andriani
3. NIP : 19760120 200312 2001
4. Jabatan / Golongan : Lektor/ III C
5. Instansi : Fakultas Kedokteran Universitas Lampung
6. Publikasi : Acta Biochimica Indonsiana, Vol 5 (1)2022.
7. ISSN : 2654 - 3222
8. Website/Email : <https://pbbmi.org/newjurnal/index.php/actabioina/article>
9. Email : evikurniawatydr@gmail.com

Bandar Lampung, 25 Juli 2022

Mengetahui,  
Dekan FK Unila



Prof. Dr. Dyah Wulan Sumekar RW, S.K.M., M. Kes  
NIP. 19720628 1997022001

Penulis,

Dr. dr. Evi Kurniawaty, M.Sc.  
NIP. 19760120 200312 2001

Menyetujui


Ketua Lembaga Penelitian dan Pengabdian  
Universitas Lampung



Dr. Lusmeilia Afriani, D.E.A  
NIP. 196505101993032008

DOKUMENTASI LEMBAGA PENELITIAN DAN PENGABDIAN KEPADA MASYARAKAT UNIVERSITAS LAMPUNG	
TGL	27/07/2022
NO. INVEN	979/S/A/N/FK/2022
JENIS	Jurnal
PARAF	J

# Ethanol extract of *Bruguiera gymnorrhiza* mangrove leaves and propolis activity on macroscopic healing of cuts *in vivo*



Evi Kurniawaty<sup>1\*</sup> , Shina Megaputri<sup>1</sup>, Syazili Mustofa<sup>1</sup> , Soraya Rahmanisa<sup>1</sup>, Kholis A. Audah<sup>2</sup> , Silvia Andriani<sup>3</sup> 

## ABSTRACT

**Background:** *Bruguiera gymnorrhiza* mangrove and propolis are often used as natural wound treatments. Its constituent is believed to promote wound healing.

**Objective:** This study aims to explore the effect of topical administration of ethanol extract of *B. gymnorrhiza* mangrove leaves and propolis on wound healing activity.

**Methods:** Twenty-four Sprague Dawley rats were randomly assigned to one of four treatment groups (n=6): aqua dest, standard wound medicine, ethanol extract of *B. gymnorrhiza* mangrove leaves, and propolis extract. Following the incision, treatment was given once a day for 14 days or until the wound healed. The cut area was observed by measuring the cut length using a ruler.

**Results:** Standard wound medication took 9 days to promote healing, while the negative control (aqua dest) took 11.2 days, the ethanol extract of *B. gymnorrhiza* mangrove leaves took 7.3 days, and the propolis extract took 7.9 days.

**Conclusions:** Topical administration of *B. gymnorrhiza* mangrove leaves ethanol extract and propolis had equal effects on the healing of wounds. Both are more effective than conventional wound ointments at healing cuts.

**Keywords:** *Bruguiera gymnorrhiza*, propolis, cuts, wound healing

## Introduction

The skin is the body's largest organ, and it serves several important purposes including providing physical protection, immunologic defense, regulating body temperature, sensing, cosmetics, and vitamin D synthesis [1]. When trauma occurs, the skin's function as physical protection is disrupted, causing other functions to be impacted. A wound is one type of skin trauma that occurs frequently [2]. Various factors, such as sharp or blunt objects, changes in temperature, chemical compounds, explosions, electric shocks,

and animal bites, can create wounds, which are damage to the integrity of tissue components [3]. Cuts are large incisions with flat edges and shallow wound walls that form a line parallel to the skin [4]. In normal circumstances, the skin compensates for wounds through a healing process that begins on the seventh day and is complete after fourteen days. Three stages comprise the wound healing process: inflammatory, proliferative, and remodeling.

Biodiversity in Indonesia possesses the potential to produce phytopharmaceuticals and novel chemicals for wound healing [5]. Mangrove *B. gymnorrhiza* plant and propolis are among often utilized natural wound remedies. Bioactive compounds found in mangrove plants, including tannins, saponins, terpenoids, flavonoids, alkaloids, and steroids, can be employed as antioxidants to stop tissue deterioration and promote wound healing [6,7].

<sup>1</sup>Department of Biochemistry and Biomolecular, Faculty of Medicine, University of Lampung, Lampung, 35141, Indonesia

<sup>2</sup>Department of Biomedical Engineering, Faculty of Life Sciences and Technology, Swiss German University, Tangerang, Indonesia

<sup>3</sup>Departement of Biology, Faculty of Mathematics and Natural Sciences, University of Lampung, 35141, Indonesia

\*Corresponding author: Jl. Prof. Dr. Ir. Sumantri Brojonegoro No. 1, Bandar Lampung 35141, Indonesia. E-mail: [evikurniawatydr@gmail.com](mailto:evikurniawatydr@gmail.com)

Propolis, or bee glue, is a substance in the form of sap (resin) collected by honey bees from various types of plants [8]. Propolis is used to paste leaking bee charcoal and avoid pests and rotting eggs. The use of propolis as medicine has been done since the 12th century by the Greeks and Romans to treat swelling [9]. Several studies reported propolis has biological properties such as flavonoids, alkaloids, tannins, saponins, and steroids that can be used for wound treatment [10,11].

Standard wound ointment contains neomycin sulfate at a concentration of 0.5%, placenta extract at a concentration of 10%, and a gel basis. Frequent use of topical medications for wound healing can produce skin irritation, marked by the appearance of red spots on the skin. For example, neomycin sulfate frequently produces hypersensitivity reactions [12]. Therefore, the use of safe medicine for healing is required. This study aims to explore the effectiveness of mangrove leaves and propolis as wound healing agents.

## Methods

### Extraction

The *B. gymnorrhiza* mangrove leaves were obtained from the Lampung Mangrove Center, Margasari Village, Labuhan Maringgai District, East Lampung Regency, Lampung, Indonesia. The old and fresh mangrove leaves were washed with water, then dried in oven at 40°C. The leaves were grounded into a fine powder (*simplicia*). The fine powder was extracted twice with 96% ethanol. The filtrate was obtained by filtering the sample through Whatman filter paper and then evaporating it at 50°C using a rotary evaporator [13].

Propolis sample was pure propolis extract under the brand name EZ Trigona (manufactured by Namaste Organics, Bandung), which contains 100% Bee Pollen from Indonesian wild Trigona bees and was tightly wrapped.

### Phytochemical determination

In order to detect saponins, 5 mL of distilled water was added to 0.5 mL of extract, which was

then agitated for 10 seconds. The formation of foam indicates the presence of saponins. In order to detect terpenoids, three drops of Liebermann-Burchard reagent (glacial acetic acid + concentrated  $H_2SO_4$ ) were added to 0.5 mL of extract. A positive triterpenoid test reveals a color of red or purple. In order to detect tannins, three drops of 1%  $FeCl_3$  solution was added to 1 mL of extract. A blackish-green or dark blue served as an indication of positivity.

Five drops of chloroform and five drops of Mayer's reagent were added to 0.5 mL of extract to detect alkaloids. The presence of alkaloids was indicated by the formation of a color ranging from white to brown. Flavonoids were identified by mixing 0.5 g of Mg powder with 0.5 mL of extract, followed by the addition of 5 mL of concentrated HCl dropwise. In the presence of foam, the formation of a red or yellow-colored solution indicated the presence of flavonoids.

### Animals

This study was experimental and used a post-test-only control group design. This research has been approved by the Research Ethics Commission of the Faculty of Medicine at the University of Lampung (approval number 3031/UN26.18/PP.05.02.00/2020). Twenty-four white rats (*Rattus norvegicus*) of the Sprague Dawley strain were randomly divided into four groups: negative control (aqua dest treatment), positive control (bioplacenton treatment), ethanol extract of *B. gymnorrhiza* mangrove leaves, and propolis extract treatment.

### Cut experiment model

The first procedure consisted of shaving the rat's back fur using a razor. The rats were anesthetized using topical lidocaine before being slashed using a sterile scalpel No.11 with a length of approximately 2 cm and a depth of 2 mm, or up to the dermis layer. Following the incision, treatment was administered once a day for 14 days or until the wound healed. In the negative control group, the wounds were washed with sterile water and

**Table 1.** Phytochemical test of *Bruguiera gymnorhiza* mangrove leaves extract

Phytochemical test	<i>Bruguiera gymnorhiza</i> leaves extract
Saponins	+
Terpenoids	-
Tannins	+
Alkaloids	-
Flavonoids	+

then covered with sterile gauze. In the positive control group, conventional wound medication was applied to the wound. The treatment groups consisted of an ethanol extract of *B. gymnorhiza* mangrove leaves and an extract of propolis. A smear of up to 0.2 mL was performed and then covered with sterile gauze.

The cut area was observed by measuring the cut length using a ruler. The obtained data were recorded daily for fourteen days. Based on the cut length observation, it was determined that the wound healed in days.

### Data analysis

The data were displayed as mean  $\pm$  SD using Prism Grappad 9.0 (San Diego, USA). Statistical analysis was performed using One Way ANOVA, and post hoc LSD test was used to determine the significance of the differences.

### Results

The mangrove leaves of *B. gymnorhiza* contain saponins, tannins, and flavonoids, but no terpenoids or alkaloids. Solvents used for extraction affects the amount of secondary metabolites extracted. In this study, ethanol was used as the solvent. The test results revealed that the extract of *B. gymnorhiza* leaves contain flavonoids, saponins, and tannins and could suppress microbial activity and promote wound healing.

Observations of cuts in rats were carried out every day for 14 days. The wound healing results were obtained from measuring the incision length. The average healing time for wounds in

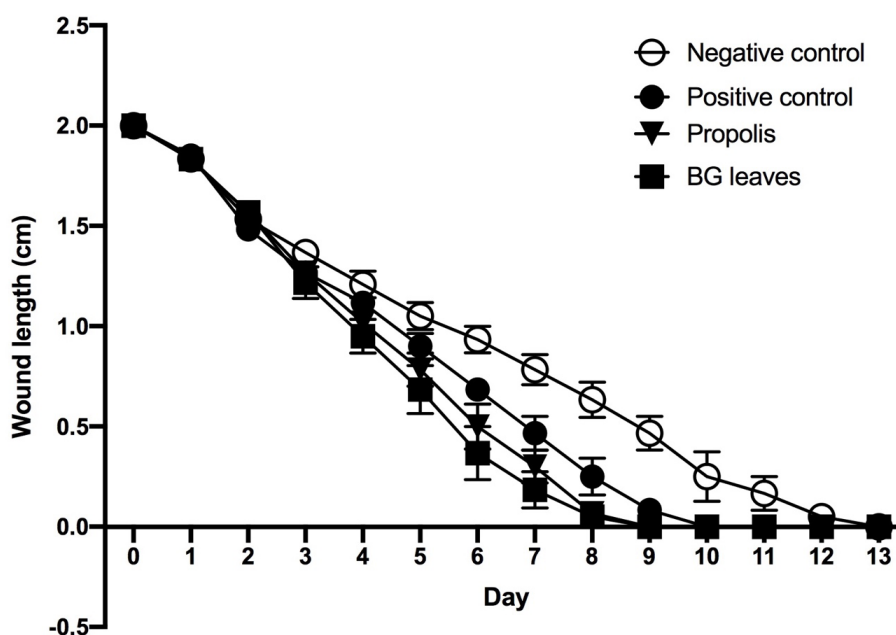
the group treated with distilled water was 11.2 days, with the quickest healing occurring in 10 days and the longest in 13 days. The average wound healing time for the conventional wound ointment group was 9 days, with the quickest healing occurring in 8 days and the longest in 10 days.

In the group that received *Bruguiera gymnorhiza* mangrove leaves extract, the average time for wound healing was 7.3 days, with the quickest healing occurring in 6 days and the slowest occurring in 9 days. In the propolis extract treatment group, the average time for a wound to heal was 7.9 days, with the quickest healing occurring in 6 days and the slowest occurring in 9 days (Figure 1). Based on the Post-Hoc LSD test, there is a significant difference between the negative control, the positive control, and both treatment groups in terms of wound healing duration.

### Discussion

Ethanol extract of *B. gymnorhiza* mangrove leaves and propolis have potential in macroscopic wound healing time in male white Sprague dawley rats, while the group of cuts washed with aqua dest took the longest time to heal, indicating that the emergence of clinical symptoms of an inflammatory reaction and a reduction in the size of the wound in rats.

The skin responds to injuries with a healing process (repair), a response from connective tissue, and cell renewal. In normal circumstances, the wound healing process in humans begins on the seventh day and lasts for 14 days. The conventional wound ointment group had the second-longest



**Figure 1.** Wound length after treated with propolis, *B. gymnorrhiza* (BG) mangrove leaves extract. In One Way ANOVA test,  $p = 0.00$ , where  $P < 0.05$  indicated a group with a significant difference in the duration of wound healing.

average wound healing time, at 9 days. As a topical therapy for external wound healing, standard wound ointments have been clinically evaluated. This conventional wound ointment includes 0.5% neomycin sulfate, 10% placenta extract ex biove, and a gel basis [12]. Placenta extract functions as a biogenic activator that hastens cell regeneration and wound healing, whereas neomycin sulfate is an antibiotic. Neomycin might nonetheless produce hypersensitivity responses. According to the literature, conventional wound ointments only speed wound healing during the proliferative phase. In this study, the ethanol extract of *B. gymnorrhiza* mangrove leaves and propolis extract promoted faster wound healing than conventional wound ointment.

The group that received an extract of *B. gymnorrhiza* mangrove leaves had the quickest average wound healing period, at 7.3 days. This demonstrates that the extract is superior to conventional wound ointments for accelerating wound healing. According to prior research, the administration of *B. gymnorrhiza* bark extract affected the healing of wounds treated with silver sulfadiazine, a standard wound medication. The ethanol extract of the mangrove leaves of *B. gymnorrhiza* contains several flavonoid and

terpenoid, tannins and steroids, alkaloids, and low saponins. [13].

The propolis extract group healed wounds in an average of 7.9 days. This result is consistent with prior studies in which postoperative incisions healed in 17 days in a group of white rats given propolis; this is faster than other treatments with silver sulfadiazine and bepanthane cream, a typical medicine used to cure wounds [14]. The extract of propolis contains alkaloids, flavonoids, terpenoids, tannins, and a low amount of steroids and saponins [8,15].

In addition to being antibacterial, flavonoids can stop bleeding in wounds, protect cells, increase vascularity, and reduce edema [16]. Tannins can reduce mucosal permeability, thereby preventing bleeding and infection, promoting the formation of fibroblasts and capillary blood vessels, and inhibiting the permeability of bacteria [17]. Saponins can stimulate the formation of collagen and have antiseptic and antibacterial properties [18,19].

## Conclusion

Both ethanol extract of *B. gymnorrhiza* mangrove leaves and propolis were better in healing cuts than

standard wound medicine and showed excellent at healing cuts.

## Acknowledgment

Thanks for Agil Patria Putra for proofreading this manuscript.

## Author contributions

EK, SM, KAA conceived the concept for the study. EK, SM, SR, SA conducted the study. EK, SA, SR wrote the first manuscript. EK, KAA reviewed and edited the manuscript. All authors have read and approved the final manuscript.

## Declaration of interest

We declare no any potential conflict of interests.

Received: 20 June 2022

Revised: 21 July 2022

Accepted: 22 July 2022

Published online: 24 July 2022

## References

- Kim JY, Dao H. Physiology, Integument. StatPearls. Treasure Island (FL): StatPearls Publishing; 2022.
- Kalangi SJ. Histofisiologi kulit. JBM. 2014;5. <https://doi.org/10.35790/jbm.5.3.2013.4344>
- Nurmalasari Y, Nofita N, Warganegara E, Sijabat AI. Perbandingan air perasan daucus carota L. dengan povidone iodine topikal dalam penyembuhan luka insisi mencit. 2020;12: 673-679. <https://doi.org/10.35816/jiskh.v12i2.378>
- Lotfollahzadeh S, Burns B. Penetrating Abdominal Trauma. StatPearls. Treasure Island (FL): StatPearls Publishing; 2022.
- Halim E, Hardinsyah H, Sutandyo N, Sulaeman A, Artika M, Harahap Y. Kajian bioaktif dan zat gizi propolis indonesia dan brasil. jgizipangan. 2013;7: 1. <https://doi.org/10.25182/jgp.2012.7.1.1-7>
- Sur TK, Hazra A, Hazra AK, Bhattacharyya D. Antioxidant and hepatoprotective properties of Indian Sunderban mangrove Bruguiera gymnorrhiza L. leave. J Basic Clin Pharm. 2016;7: 75-79. <https://doi.org/10.4103/0976-0105.183262>
- Syahidah, Subekti N. Phytochemical Analysis of Mangrove Leaves (*Rhizophora* sp.). IOP Conf Ser: Mater Sci Eng. 2019;593: 012007. <https://doi.org/10.1088/1757-899X/593/1/012007>
- Wagh VD. Propolis: a wonder bees product and its pharmacological potentials. Adv Pharmacol Sci. 2013;2013: 308249. <https://doi.org/10.1155/2013/308249>
- Coutinho A. Honeybee propolis extract in periodontal treatment: a clinical and microbiological study of propolis in periodontal treatment. Indian J Dent Res. 2012;23: 294. <https://doi.org/10.4103/0970-9290.100449>
- Cornara L, Biagi M, Xiao J, Burlando B. Therapeutic Properties of Bioactive Compounds from Different Honeybee Products. Front Pharmacol. 2017;8: 412. <https://doi.org/10.3389/fphar.2017.00412>
- Salatino A, Salatino MLF, Negri G. How diverse is the chemistry and plant origin of Brazilian propolis? Apidologie. 2021;52: 1075-1097. <https://doi.org/10.1007/s13592-021-00889-z>
- Bioplacenton KalbeMed [Internet]. [cited 20 Jul 2022]. Available: <https://kalbemed.com/product/id/101>
- Anggraini RR, Hendri M, Rozirwan R. Potensi larutan bubuk daun mangrove *Bruguiera gymnorrhiza* sebagai pengawet alami. Maspari Journal : Marine Science Research. 2018;10: 51-62.
- Khorasgani EM, Karimi AH, Nazem MR. A Comparison of Healing Effects of Propolis and Silver Sulfadiazine on Full Thickness Skin Wounds in Rats. Pakistan Veterinary Journal. 2010;30: 72-74.
- Khairunnisa B, Rosamah E, Kuspradini H, Kusuma IW, Sukemi S, Tandirogang N, et al. Uji fitokimia dan antioksidan ekstrak etanol propolis lebah kelulut (*Tetragonula iridipennis*) dari Samarinda Kalimantan Timur. Jurnal Ilmiah Manuntung. 2020;
- Chittasupho C, Manthaisong A, Okonogi S, Tadtong S, Samee W. Effects of quercetin and curcumin combination on antibacterial, antioxidant, in vitro wound healing and migration of human dermal fibroblast cells. Int J Mol Sci. 2021;23. <https://doi.org/10.3390/ijms23010142>
- Fernandez O, Capdevila JZ, Dalla G, Melchor G. Efficacy of *Rhizophora mangle* aqueous bark extract in the healing of open surgical wounds. Fitoterapia. 2002;73: 564-568. [https://doi.org/10.1016/S0367-326X\(02\)00229-0](https://doi.org/10.1016/S0367-326X(02)00229-0)
- Ibrahim N 'Izzah, Wong SK, Mohamed IN, Mohamed N, Chin K-Y, Ima-Nirwana S, et al. Wound healing properties of selected natural products. Int J Environ Res Public Health. 2018;15. <https://doi.org/10.3390/ijerph15112360>
- Liu E, Gao H, Zhao Y, Pang Y, Yao Y, Yang Z, et al. The potential application of natural products in cutaneous wound healing: A review of preclinical evidence. Front Pharmacol. 2022;13. <https://doi.org/10.3389/fphar.2022.900439>