

PAPER NAME

jurnal 2022.pdf

AUTHOR

evi kurniawaty

WORD COUNT

4145 Words

CHARACTER COUNT

21153 Characters

PAGE COUNT

8 Pages

FILE SIZE

911.9KB

SUBMISSION DATE

May 13, 2022 1:39 PM GMT+7

REPORT DATE

May 13, 2022 1:40 PM GMT+7

● 9% Overall Similarity

The combined total of all matches, including overlapping sources, for each database.

- 7% Internet database
- Crossref database
- 4% Submitted Works database
- 4% Publications database
- Crossref Posted Content database

● Excluded from Similarity Report

- Bibliographic material
- Cited material
- Quoted material
- Small Matches (Less than 10 words)



ORIGINAL ARTICLE

The Effect of Mangrove Leaf Extract (*Bruguiera Gymnorhiza*) on the Histopathology of the Skin of White Rats (*Rattus Norvegicus*) Which Has Been Subjected

Evi Kurniawaty^{1*}, M. Panji Marga², Intanri Kurniati³, Kholis A.Audah⁴, Silvia Andriani⁵

*Corresponding Author: Evi Kurniawaty

Abstract:

Wound healing is a complex process and focuses on restoring the continuity of damaged tissue. The healing process of serious wounds requires proper care to prevent wider tissue damage. Untreated open wounds have the potential to develop infections such as gangrene and tetanus if left untreated. The content of mangrove extracts that can be used as a treatment include flavonoids, saponins, terpenoids, and alkaloids. This research is an experimental study with a completely randomized design (CRD) with a Posttest Only Control Group Design approach. This research was conducted for 14 days. The samples used were 24 rats which were divided into 3 groups, namely group K- given 2 ml of distilled water/day, group K1 given 40% mangrove leaf extract at a dose of 0.2 ml/day, and group K2 given 80% mangrove leaf extract. % with a dose of 0.2 ml / day. Calculation of cellular infiltration, collagen, epithelium and angiogenesis were assessed based on the Karayannopoulou score (2011). Data were analyzed using One-Way ANOVA and Post Hoc LSD statistical tests. Based on the results of the One-Way ANOVA statistical test, p value = 0.000 (p <0.05) in all variables. Based on the results of the Post Hoc LSD statistical test on cellular infiltration, collagen, epithelium, and angiogenesis showed significant differences (p<0.05). There is an effect of giving extracts of mangrove leaves (*Bruguiera gymnorhiza*) on the histopathology of the skin of white rats (*Rattus norvegicus*) with cuts.

Keywords: mangrove, *Bruguiera gymnorhiza*, and cuts

Introduction:

Wounds are the loss or destruction of part of the body's tissues. This condition can be caused by sharp or blunt trauma, temperature changes, chemicals, explosions, electric shocks, or animal bites. Wounds can take various forms, for example cuts or vulnus scissum caused by sharp objects, while stab wounds or vulnus punctum are caused by sharp objects. The skin as the main function as a barrier barrier between the human body and the external environment, as well as

protecting the body against chemical and physical factors. The skin plays a role in metabolic processes, absorption, thermoregulation and immunological processes. In addition, the skin is also the first line of defense against pathogenic microorganisms.

If there is an injury to the skin tissue, there will be an automatic physiological response process in the body through three phases of the healing process, namely the inflammatory phase, the proliferative

^{1,2,3} Faculty of Medicine, University of Lampung, Lampung, Indonesia

⁴ Department of Biomedical Engineering, Faculty of Life Sciences and Technology, Swiss German University, Tangerang, Indonesia

⁵ Departement of Biology, Faculty of Mathematics and Natural Sciences, University of Lampung

¹ Supplementary information The online version of this article contains supplementary material, which is available to authorized users. Ferjaoui Wael 2022; Published by Current Science, Inc. This Open Access article is distributed under the terms of the Creative Commons License (<http://creativecommons.org/licenses/by/4.0>), which permits unrestricted use, distribution, and reproduction in any medium, provided the original work is properly cited

phase, and the remodeling phase. Wound healing is a complex process and focuses on restoring tissue continuity. Wound care and treatment are the main factors determining the final outcome of the wound healing process. So that drugs containing anti-inflammatory agents and antibiotics are indispensable in preventing infection and accelerating the wound healing process.

One treatment can use mangroves as a source of natural antimicrobials, because they contain compounds such as alkaloids, phenols, flavonoids, steroids, saponins, and terpenoids or commonly known as secondary metabolites that can suppress microbial growth. Based on research conducted by Dia *et al.*, (2015) mangrove leaf extract (*Bruguiera gymnorhiza*) contains phenol and steroid bioactive components that function as antioxidants and antibacterials. The components of phenolic compounds and steroids in the leaves were found to be higher than the bark and root extracts of mangrove plants (*Bruguiera gymnorhiza*).

Based on the description above, researchers have an interest in how the effect of giving mangrove leaf extract (*Bruguiera gymnorhiza*) on the histopathology of white rat skin (*Rattus norvegicus*) with cuts is still a little found, therefore researchers want to prove whether there is an effect of giving mangrove leaf extract (*Bruguiera gymnorhiza*) on the histopathology of the skin of white rats (*Rattus norvegicus*) with cuts.

1. Methode

This research is an experimental study with a completely randomized design method and with a Post Test Only Control Group Design approach. The population in this study were male white rats

(*Rattus norvegicus*) with the *Sprague Dawley* strain with inclusion criteria being healthy and looking active, weighing 150-200 grams, aged about 10-15 weeks, male sex and exclusion criteria, among others, There was a decrease in body weight more than 10% after the adaptation period in the laboratory, and Dies during the treatment period.

The 24 rats were divided into three groups of ten in each group and placed in three different cages. Mice went through an adaptation period of one week before the treatment started. Before making a wound, the hair around the wound area is shaved according to the desired incision area. After shaving, perform an anesthetic procedure for subcutaneous superficial surgery using lidocaine 0.2-0.4 ml/kgBW so that the rat does not feel pain and avoids excessive movement that will be caused by the rat.

Slight scratches were made on the skin of rats with cuts and then taken for making microscopic preparations using the paraffin method and Hematoxylin Eosin (HE) staining. Cutting using a rotary microtome using a disposable knife. Paraffin ribbons were spread in a water bath at 60°C. Followed by hematoxylin eosin staining. Giving aquadest to the wound once a day for 14 days, cleaned with distilled water and given 40% mangrove leaf extract given once a day for 14 days. Samples were sent to the Lab. Histology and Anatomical Pathology, Faculty of Medicine, Unila for the manufacture of preparations.

2. Research Result

Microscopic images were interpreted in 5 fields of view using a 400x magnification light microscope and then assessed from observations on cellular infiltration, collagen formation, epithelium and angiogenesis.

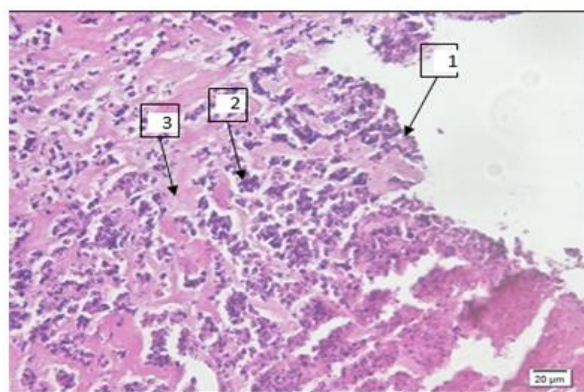


Figure 1. Negative Control Group (K-) (light microscope magnification 400x) Description: 1. Epithelium; 2. Cellular Infiltration; 3. Collagen

In the histopathological picture of the skin in the K- group, more inflammatory cell infiltration was found than in the K1 and K2 groups, the

formation of less collagen production, the thickness of the epithelium was not yet formed, and no new blood vessels were found.

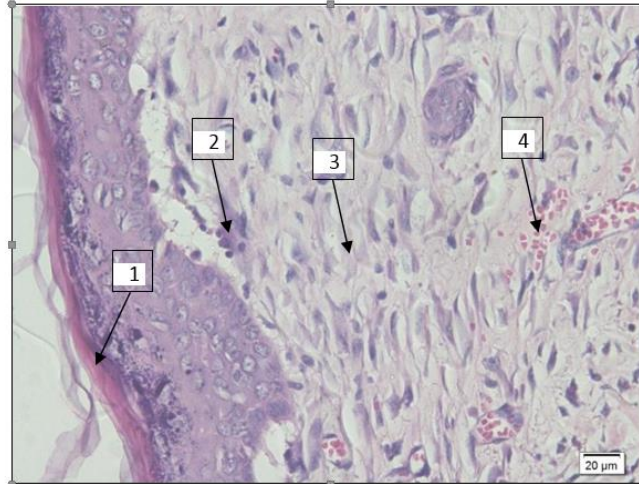


Figure 2. Treatment Group 1 (K1) (light microscope magnification 400x) Description: 1. Epithelium; 2. Cellular Infiltration; 3. Collagen; 4. Angiogenesis.

In the histopathological description of the skin in the K1 group, there was less inflammatory cell infiltration than the K- group, the formation of

more collagen production, an increase in epithelial thickness was visible, and new blood vessels were found.

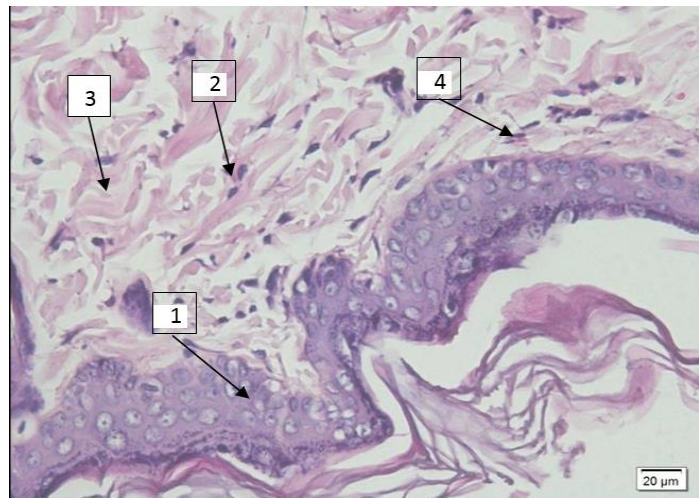


Figure 3. Treatment Group 2 (K2) (light microscope magnification 400x) Description: 1. Epithelium; 2. Cellular Infiltration; 3. Collagen; 4. Angiogenesis.

In the histopathological description of the skin in the K2 group, there was less inflammatory cell infiltration than the K- and K1 groups, the formation of collagen production was very clear, the epithelium was thicker than the K- and K1 groups, and there was an increase in new blood vessels.

The data obtained from histopathological observations under a microscope were tested for statistical analysis using the SPSS program. The results of the study were data normality test using the *Saphiro-Wilk* test to assess the normality of the data distribution. The Shapiro-Wilk test was carried out because the number of samples studied was 50. The results of the *Shapiro-Wilk* normality test are presented in table 1.

Table 1. Shapiro-Wilk . Normality Test

Grup	Shapiro-Wilk		Normality test	
	Infiltrasi Celuler	collagen	Epithellium	Angiogenesis
K-	0,197	0,175	0,197	0,197
K+	0,563	0,542	0,410	0,120
	0,446	0,862	0,801	0,093

The Shapiro-Wilk normality test was considered significant if $p > 0.05$ in all groups. The results of the normality test that have been carried out in all groups show a p value > 0.05 so that the overall data is normally distributed. Then, the One-Way

ANOVA hypothesis test was conducted because the data were normally distributed. One-Way ANOVA hypothesis test is considered significant if the p value < 0.05 . The results of the One-Way ANOVA hypothesis test are presented in the table.

Table 2. One-Way ANOVA Test

Test	Infiltrasi Celuler	collagen	Epithellium	Angiogenesis
Anova	0,001	0,001	0,001	0,001

Based on the One Way ANOVA test table, the p value is 0.000^* (H_0 is rejected, H_1 is accepted) so that in this study it can be concluded that there is an effect of administering mangrove leaf extract (*Bruguiera gymnorrhiza*) on the histopathology of the skin of white rats (*Rattus norvegicus*) with

wounds. I t. After the One-Way ANOVA hypothesis test was declared significant ($p < 0.05$), a Post Hoc-LSD analysis test was conducted to see the differences in each group. The results of the Post Hoc-LSD analysis test are presented in table

Table 3. Post Hoc LSD Test

Variable	Grup	Grup	p -value
Infiltrasi Celluler	K (-)	K 1	0,003*
		K 2	0,000*
	K 1	K (-)	0,003*
		K 2	0,000*
	K 2	K (-)	0,000*
		K 1	0,000*
Collagen	K (-)	K 1	0,000*
		K 2	0,000*
	K 1	K (-)	0,000*
		K 2	0,000*
	K 2	K (-)	0,000*
		K 1	0,000*
Epithellium	K (-)	K 1	0,000*
		K 2	0,000*
	K 1	K (-)	0,000*
		K 2	0,008*
	K 2	K (-)	0,000*

Angiogenesis	K (-)	K 1	0,008*
		K 1	0,000*
	K 1	K 2	0,000*
		K (-)	0,000*
	K 2	K 2	0,000*
		K (-)	0,000*
	K 1	0,000*	

Based on the Post Hoc LSD test table, it is known that the cellular infiltration has a significant difference in all groups ($p < 0.05$), namely groups K(-) and K1 ($p = 0.003$), groups K(-) and K2 ($p = 0.000$), groups K1 and K2 ($p = 0.000$), groups K2 and K(-) ($p = 0.000$), groups K2 and K1 ($p = 0.000$)

$p = 0.000$), groups K1 and K(-) ($p = 0.003$), groups K1 and K2 ($p = 0.000$), groups K2 and K(-) ($p = 0.000$), groups K2 and K1 ($p = 0.000$)

Table. 4 Skin Damage Skor

Grub	Sample	Mean Skor			
		Infiltrasi Seluler	Collagen	Epithel	Angiogenesis
K -	1	4,6	1,6	0,6	1
	2	4,8	1,8	0,4	1,2
	3	5	1,2	0,2	1,4
	4	4,6	1,6	0,8	1
	5	5	2	0,4	1,4
	6	4,8	1,8	0,8	1,2
	7	5	2	0,6	1,4
	8	4,4	1,2	0,8	0,8
Total Average		4,775	1,65	0,575	1,175
K 1	1	4,8	2,8	1,4	1,8
	2	4,2	3,6	2,2	2
	3	3,8	4	2,4	1,6
	4	3,8	3,6	1,4	1,6
	5	4,4	3,2	1,8	1,4
	6	4,2	3,4	2	1,4
	7	4,4	4	2,2	1,6
	8	4	3,8	1,6	1,4
Total Average		4,2	3,55	1,875	1,6
K 2	1	3,8	3,8	1,8	2,6
	2	4,2	4	2,2	2,8
	3	3,8	4,4	2	2,8
	4	3,4	4,2	2,4	2,6
	5	3,4	4,6	2,6	2,6
	6	3	4,8	2,8	2,4
	7	3	4,6	2,4	2,4
	8	3,2	4,2	2,6	2,6
Total Average		3,475	4,325	2,35	2,6

In the analysis of the histopathological picture of rat skin damage obtained from cellular infiltration, collagen production, epithelial thickness, and angiogenesis taken from five fields of view, then averaged in each group, so that the average value of the cellular infiltration damage score in the K group is obtained. only given aquadest in the amount of 4.775; in group K1 given 40%

mangrove leaf extract for 14 days, the average damage score was 4.2; in group K2 given 80% mangrove leaf extract for 14 days, the mean score was 3,475.

There was an increase in the mean value in the treatment group which was indicated by reduced inflammatory cell infiltration. In the mean score of

damage to collagen formation in the K-group which was only given aquadest, it was 1.65; in group K1 given 40% mangrove leaf extract for 14 days, the average damage score was 3.55; in group K2 given 80% mangrove leaf extract for 14 days, the mean score was 4.325; there was an increase in the mean value in the treatment group which was marked by a clear picture of collagen formation.

The mean score of epithelial damage in the K-group which was only given aquadest was 0.575; in group K1 given 40% mangrove leaf extract for 14 days, the average damage score was 1.875; in group K2 given 80% mangrove leaf extract for 14 days, the mean score was 2.35; there was an increase in the mean value in the treatment group which was indicated by an increase in epithelial thickness. The average angiogenesis score for the K-group that was only given aquadest was 1.175; in group K1 given 40% mangrove leaf extract for 14 days, the average damage score was 1.6; in group K2 given 80% mangrove leaf extract for 14 days, the mean score was 2.6; there was an increase in the mean value in the treatment group which was indicated by the number of new blood vessels.

4. Discussion

The results of microscopic observations showed that the average cellular infiltration scores in the K-, K1, and K2 groups were 4.775; 4.2; and 3.475 which showed that there was an effect of administration of mangrove leaf extract (*Bruguiera gymnorrhiza*) on the histopathology of the skin of white rats (*Rattus norvegicus*) with cuts. The average number of cellular infiltration in the negative control group showed the highest results, this was due to the absence of active ingredients given to the skin of white rats that suffered cuts so that the number of inflammatory cells and skin tissue damage was different in the groups given the treatment.

This is in line with the research by Gunawan *et al.*, (2019) that on day 14 cellular infiltration in the control group was still found, while in the treatment group it was no longer found. In addition, flavonoid compounds act as anti-inflammatory compounds that can inhibit the secretion of lysosomal enzymes in the inflammatory process, this can accelerate the inflammatory phase so that the proliferation phase

and remodeling phase will occur more quickly (Fridiana, 2012).

In microscopic observations, the average collagen scores in the K-, K1, and K2 groups were 1.65; 3.55; and 4.325 which indicated that there was an effect of giving extracts of mangrove leaves (*Bruguiera gymnorrhiza*) on the histopathology of the skin of white rats (*Rattus norvegicus*) with cuts.

The highest mean amount of collagen was found in treatment group 2 (K2). This is in line with research conducted by Amita *et al.*, (2017) on the histopathological description of wound healing in mice given binahong extract which also contains active compounds of flavonoids and saponins. compared to the negative control group which was only given aquades.

Saponin compounds found in mangrove leaf extract (*Bruguiera gymnorrhiza*) can trigger an increase in collagen during the wound healing process which is characterized by an increase in the microscopic appearance of collagen in groups K1 and K2. In addition, the terpenoid compounds contained in the extract of mangrove leaves (*Bruguiera gymnorrhiza*) can increase the percentage of collagen by stimulating the formation of the extracellular matrix.

Other ingredients that play a role in the process of strengthening collagen fibrils so that they are able to prevent cell damage, accelerate and strengthen the growth of new tissue are alkaloid compounds (Poernomo & Setiawan, 2019). During the proliferative phase, fibroblast proliferation occurs. Fibroblasts will produce collagen which will then link the wound so that the wound will be closed. Collagen plays an important role in accelerating the wound healing process because it can trigger protein synthesis, cell differentiation, matrix deposition, angiogenesis, epithelialization, wound contraction, platelet aggregation, and can induce the coagulation cascade. maturation/remodeling will take place soon.

In microscopic observations, the average epithelial scores in the K-, K1, and K2 groups were 0.575; 1.875; and 2.35 which indicated that there was an effect of giving extract of mangrove leaves (*Bruguiera gymnorrhiza*) on the histopathology of the skin of white rats (*Rattus norvegicus*) with cuts. The best epithelial thickness was found in treatment group 2 (K2). This is in accordance with

the theory that mangrove leaf extract contains anti-inflammatory agents such as flavonoids, saponins, and terpenoids that can accelerate the wound healing process so that epithelial formation is more clearly seen in the treatment group (Ernianingsih *et al.*, 2014).

Several parameters are indicators of the wound healing process, namely epithelialization, an increase in the number of fibroblast cells, and an increase in the number of PMN cells in the early phase of inflammation. Epithelialization process occurs in the proliferative phase. The content of active saponins in mangrove leaf extract (*Bruguiera gymnorrhiza*) can modify the TGF receptor so that it can stimulate fibroblasts to synthesize fibronectin which has an important role as a mediator of extracellular matrix components which can then direct epithelial cells to cross the wound area so that the epithelialization process can take place more quickly. The content of flavonoids is also known to have an important role in wound contraction and accelerate the epithelialization process. The faster the re-epithelialization process, the faster the wound will close and the wound healing process will also be faster.

In microscopic observations, the average angiogenesis score in the K-, K1, and K2 groups was 1.175, respectively; 1.6; and 2.6, which indicates that there is an effect of giving mangrove leaf extract (*Bruguiera gymnorrhiza*) on the histopathology of the skin of white rats (*Rattus norvegicus*) with cuts. The formation of new blood vessels was mostly found in treatment group 2 (K2). This is because in the extract of mangrove leaves (*Bruguiera gymnorrhiza*) it contains saponin compounds that can stimulate the growth of new cells, including the growth of vascular endothelial cells, fibroblast cells, and smooth muscle cells of blood vessels so that they can repair the walls of blood vessels that have suffered damage. In addition to collagen synthesis and re-epithelialization, the proliferative phase is also marked by the formation of new blood vessels (angiogenesis) (Sari *et al.*, 2019; Rosa *et al.*, 2018).

When the tissue is damaged, the angiogenesis process will occur as an effort to maintain the continuity of the various functions of the affected tissues and organs. The formation of new blood vessels plays an important role as a provider of

oxygen and nutrition for the tissues or cells that are being regenerated. In addition, the formation of new blood vessels also aims to increase vascular permeability, regulate migration and increase endothelial cell proliferation. The more new blood vessels are found, the faster the tissue repairs so that the wound healing process will be faster.

5. Conclusion

- a. There is an effect of administration of mangrove leaf extract (*Bruguiera gymnorrhiza*) on the histopathology of cellular infiltration of the skin of white rats (*Rattus norvegicus*) with cuts.
- b. There is an effect of giving extracts of mangrove leaves (*Bruguiera gymnorrhiza*) on the histopathology of collagen formation in the skin of white rats (*Rattus norvegicus*) with cuts.
- c. There is an effect of administration of mangrove leaf extract (*Bruguiera gymnorrhiza*) on the histopathology of the epithelial thickness of the skin of white rats (*Rattus norvegicus*) with cuts.
- d. There is an effect of administration of mangrove leaf extract (*Bruguiera gymnorrhiza*) on the histopathology of cellular infiltration of the skin of white rats (*Rattus norvegicus*) with cuts.

Reference

1. Agustin R, Dewi N, Rahardja SD. 2016. Efektivitas ekstrak ikan haruan (*Channa striata*) dan ibuprofen terhadap jumlah sel neutrofil pada proses penyembuhan luka. *Dentino*. 1(1): 68-74.
2. Amita K, Balqis U, Iskandar CD. Gambaran histopatologi penyembuhan luka sayat pada mencit (*Mus musculus*) menggunakan ekstrak daun binahong (*Anredera cordifolia* (Tenore) Steenis). *Jurnal Ilmiah Mahasiswa Veteriner*. 1(3): 584-591.
3. Ardananurdin A, Winarsih S, Widayat M. 2004. Uji efektifitas dekok bunga belimbing wuluh (*Averrhoa bilimbi*) sebagai antimikroba terhadap bakteri *Salmonella typhi* secara in vitro. *Jurnal Kedokteran Brawijaya*. 20(1): 30-34.
4. Arisanty IP. 2014. Manajemen perawatan luka: konsep dasar. Jakarta: EGC.

5. Bahagia W. 2018. Pengaruh pemberian ekstrak kulit batang bakau minyak (*Rhizophora apiculata*) etanol 95% terhadap histopatologi pankreas tikus putih jantan galur *Sparague dawley* yang terpapar asap rokok [skripsi]. Bandar Lampung : Universitas Lampung.
6. Darwin CO. 2016. Gambaran sel darah putih pada respon inflamasi pasca pemasangan implan yang dilapisi *platelet rich plasma* dan tanpa dilapisi *platelet rich plasma* [skripsi]. Makassar : Universitas Hasanuddin.
7. Desmania D, Harianto SP, Herwanti S. 2018. Partisipasi kelompok wanita cinta bahari dalam upaya konservasi hutan *mangrove*. Jurnal Sylva Lestari. 6(3): 28-35.
8. Dia SPS, Nurjanah, Jacob AM. 2015. Komposisi kimia dan aktivitas antioksidan akar, kulit batang dan daun lindur. Jurnal Pengolahan Hasil Perikanan Indonesia. 18(2): 205-219
9. Djuanda A. 2013. Anatomi dan Faal Kulit. Ilmu Penyakit Kulit dan Kelamin.
10. Edisi ke-6. Jakarta: Balai Penerbit FK UI.
11. Erianingsih SW, Mukarlina, Rizalinda. 2014. Etnofarmakologi tumbuhan *mangrove* *Achantus ilicifoliun*, *Acrostikum speciosum* L dan *Xylocarpus rumphii* Mabb di desa Sungai Tekong Kecamatan Kakap Kabupaten Kubu Raya. Jurnal Protobiont. 3(2): 252-258.
12. Fridiana D. 2012. Uji inflamasi ekstrak umbi rumput teki (*Cyperus rotundus* L) pada kaki tikus wistar jantan yang diinduksi karangan [skripsi]. Universitas Jember.
13. Giri C, Ochieng E, Tieszen LL, Zhu Z, Singh A, Loveland T, *et al.* 2011. Status and distribution of *mangrove* forests of the world using earth observation satellite data. Global Ecology and Biogeography. 20(1): 154-159.
14. Gonzalez AC, Costa TF, Andrade ZA, Medrado ARAP. 2016. Wound healing-A literature review. An Bras Dermatol. 91(5): 614-620.
15. Gunawan SA, Berata IK, Wirata IW. 2019. Histopatologi kulit pada kesembuhan luka insisi tikus putih pasca pemberian extracellular matrix (ECM) yang berasal dari vesica urinaria babi. Indonesia Medicus Veterinus. 8(3): 313- 324
16. Jacob AM, Purwaningsih S, Rinto. 2011. Anatomi, komponen bioaktif dan aktivitas antioksidan daun *mangrove* api-api (*Avicennia marina*). Jurnal Pengolahan Hasil Perikanan Indonesia. 14(2): 143-152.
17. James WD, Berger TG, Elston DM. 2006. Andrews' Diseases of the Skin: Clinical Dermatology. 10th edition. Philadelphia: Elsevier.
18. Kalangi SJR. 2013. Histofisiologi kulit. Jurnal biomedik. 5(3): 12-20. Karayannopoulou MV, Tsioli P, Loukopoulos T, Anagnostou N, Giannakas I,
19. Savvas L, *et al.* 2011. Evaluation of the Effectiveness of an Ointment Based
20. on Alkannins Shikonins On Second Intention Wound Healing in the Dog. The Canadian Journal of Vet. Res. 75: 42-48. Selvaraj D, Viswanadha VP, Elango S. 2015. Wound dressings – a review.
21. BioMedicine. 5(4): 24-28.
22. Sharp P, Villano J. 2012. The Laboratory of Rat. Edisi ke-2. New York: CRC Press.
23. Sjamsuhidajat R. 2010. Buku Ajar Ilmu Bedah. Edisi ke-3. Jakarta: Penerbit Buku Kedokteran EGC.
24. Susanti E. 2015. Gambaran histopatologi hati tikus putih (*Rattus norvegicus*) yang diberi insektisida golongan piretroid (sipermetrin) [skripsi]. Makassar: Fakultas Kedokteran Universitas Hasanuddin.
25. Taylor C. 2011. Fundamentals of nursing: the art and science of nursing care.
26. Edisi ke-8. Philadelphia: Lippincott Williams & Wilkins.
27. Wasitaatmodja SM. 2010. Anatomi kulit. Dalam: Djuanda A, Hamzah M, Aisah S, penyunting. Ilmu penyakit kulit dan kelamin. Edisi ke-6. Jakarta: FK UI.
28. Widiartini W, Siswati E, Setiyawati A, Rohmah IM, Prastyo E. 2013. Pengembangan usaha produksi tikus putih (*Rattus norvegicus*) tersertifikasi dalam upaya memenuhi kebutuhan hewan laboratorium. Prosiding elektronik (*e-Proceedings*) PIMNAS PKM-K.
29. Widjajanti H, Ridho MR, Munawar, Andriani O. 2015. Pengaruh ekstrak akar *Avicennia alba* dan *Rhizophora apiculata* serta konsentrasi hambat minimumnya terhadap *Vibrio* sp. (MC3P5). Garba Rujukan Digital. 431-441.
30. Wolfensohn S, Lloyd M. 2013. Handbook of Laboratory Animal. Management and Welfare, Edisi 4th. West Sussex: Wiley-Blackwell.

● 9% Overall Similarity

Top sources found in the following databases:

- 7% Internet database
- Crossref database
- 4% Submitted Works database
- 4% Publications database
- Crossref Posted Content database

TOP SOURCES

The sources with the highest number of matches within the submission. Overlapping sources will not be displayed.

1	currentscience.info	Internet	2%
2	journal.umpalangkaraya.ac.id	Internet	1%
3	Nádia S. V. Capanema, Alexandra A. P. Mansur, Sandhra M. Carvalho, ...	Crossref	<1%
4	jurnalkedokteranunsri.id	Internet	<1%
5	Neliza Utary, Krisna Murti, Indri Seta Septadina. "Effects of Moringa (M...	Crossref	<1%
6	Udayana University on 2020-01-18	Submitted works	<1%
7	ejournal.urindo.ac.id	Internet	<1%
8	stp-mataram.e-journal.id	Internet	<1%

- 9 **A Brahmanta, D Mulawarmanti, F Z Ramadhani, W Widowati. "The Diffe...** <1%
Crossref

- 10 **pbbmi.org** <1%
Internet

- 11 **repository.unmas.ac.id** <1%
Internet

- 12 **York University on 2005-11-29** <1%
Submitted works

- 13 **irep.iium.edu.my** <1%
Internet

- 14 **stat.bell-labs.com** <1%
Internet

- 15 **University of Warwick on 2009-01-22** <1%
Submitted works

- 16 **Kirani Nuranisa, Cut Fauziah, Yuli Suciati. "The Effect Of Giving Red Dr...** <1%
Crossref

- 17 **Universitas Diponegoro on 2021-05-26** <1%
Submitted works