

## Histopathological Observation of The Qurban Goat's (*Capra Aegagrus Hircus*) Lung Organs in Tulus Rejo Village, Pekalongan District, East Lampung 2019 Suspected Of Being Infected With Pneumonia

Ostarica Alqoriani A<sup>1</sup>, Hendri Busman<sup>2</sup>, Gregorius Nugroho Susanto<sup>3</sup>,  
Nuning Nurcahyani<sup>4</sup>, Nur Lailatul Arofah<sup>5</sup>.

<sup>1,2,3,4</sup> Jurusan Biologi, Fakultas Matematika dan Ilmu Pengetahuan Alam, Universitas Lampung  
Jl. Soemantri Brojonegoro no.1 Bandar Lampung, 35141

<sup>5</sup>Jurusan Kedokteran Hewan, Fakultas Kedokteran Hewan, Institut Pertanian Bogor  
Jl. Raya Dramaga, Babakan, Kec. Dramaga, Bogor, Jawa Barat 16680

Coressponding Author E-mail:

<sup>1</sup>ostaricaalqoriani@gmail.com

<sup>2</sup>Hendri\_busman@yahoo.com

<sup>3</sup>gnugrohos@gmail.com,

<sup>4</sup>nuning.nurcahyani@fmipa.unila.ac.id

<sup>5</sup>nurlailatularafah@gmail.com

Received: June 29<sup>th</sup>, 2020

Accepted: July 21<sup>st</sup>, 2020

Online Published: July 21<sup>st</sup>, 2020

### Abstract

Placement of goats of various ages and the number of animals that exceed the maximum limit in one cage can cause the spread of diseases caused by viruses, bacteria, etc. One of them can cause pneumonia. Dirt and extreme temperatures in East Lampung are feared to increase the growth of bacteria that cause pneumonia. The purpose of this research was to determine the type of pneumonia that infects and the differences between the histopathological organs of the healthy qurban goats and those infected with pneumonia. This research was conducted in October-November 2019 at the Pathology Laboratory of the Veterinary Institute of Lampung. About 13 samples of lung organ of goat qurban (*Capra aegagrus hircus*) were taken from the Baburahman mosque of Tulus Rejo Village, Pekalongan District, East Lampung. The results of the study found 6 samples of positive qurban goat lungs infected with pneumonia, with the characteristics of inflammatory cells accompanied by thickening of the septa alveoli, edema, and the presence of hemorrhage. Based on observations, the most infecting types of pneumonia are pulmonary edema and peri-bronchial edema.

**Keyword:** Pneumonia in Goats; Goats; Hypatological of Pneumonia.

### How to cite this article :

Alqoriani A., O., Busman, H., Susanto, G. N., Nurcahyani, N., & Arofah, N. L. (2020). Histopathological Observation of The Qurban Goat's (*Capra Aegagrus Hircus*) Lung Organs in Tulus Rejo Village, Pekalongan District, East Lampung 2019 Suspected Of Being Infected With Pneumonia. *IJIS Edu : Indonesian Journal of Integrated Science Education*, 2(2), 91-99. doi:<http://dx.doi.org/10.29300/ijisedu.v2i2.3324>

## INTRODUCTION

According to data from the Directorate General of Animal Husbandry and Animal Health (PKH) (2017), the goat population in Indonesia in 2017 reached 18,410,379 with Lampung being the third-largest producer of goats totaling 1,340,085 after Central Java and West Java. According to Murtidjo (1993) and Sarwono (2006), goats become one of the livestock that is favored with high economic value. Besides being sold as a market need for goat meat and milk, goats are usually traded as qurban animals. The goats that will be used as sacrificial animals are collected from various regions. As a sacrificial animal, goats must be chosen the most healthy. Generally the location of goats and feeding goats are in the same location. So that the gathering of goats from various regions is feared will reduce the health of the goats. Murtidjo (1993), explains the placement of livestock of various ages in one place and the number of animals that exceed the maximum limit in one cage can cause the spread of several diseases caused by viruses, bacteria, and etc.

Murtidjo (1993) and Sarwono (2006), explained that one of the diseases that can infect livestock is pneumonia. Corwin (2001) explains pneumonia as inflammation of the lungs that can cause inflammation manifestation in each lobe. According to Sendow *et al.*, (2002), pneumonia can infect goats by up to 15%. The high mortality rate of livestock can reach 51% due to attacks of various types of pneumonia. According to Wahid and Imam (2013), pneumonia can be caused by bacteria, viruses, and others. Fikri (2016) mentions that *Streptococcus pneumonia* is a bacterium that causes pneumonia infection. Liu *et al.* (2008), explained that *Streptococcus* bacteria reproduce best at 37 °C. Alimudin (2019) states the temperature in East Lampung in the dry season can reach 35 °C. According to Mirwansyah as Head of the East Lampung Health Office in Jaya (2017) pneumonia in East Lampung was detected and attacked quite a number of toddlers, but this is still in the data collection.

The purpose of this study was to determine the type of pneumonia that infects

and determine the histopathological differences in the lungs of qurban goats that are healthy and infected with pneumonia. If the most selected qurban goats can still be infected with pneumonia, it does not rule out the possibility that other livestock animals can be infected with a more severe level. Therefore, it is necessary to conduct research on pneumonia infection that infects qurban goats in East Lampung.

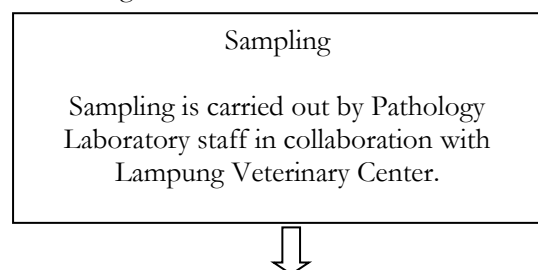
The following is a classification of goats according to Kusuma (2009) in the Hati (2016):

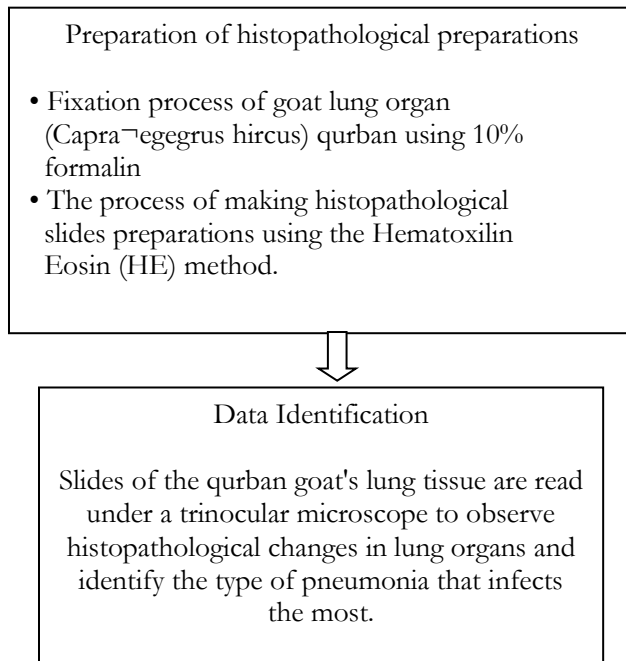
Kingdom	: Animalia
Phylum	: Chordata
Class	: Mammalia
Nation	: Artiodactyla
Tribe	: Bovidae
Marga	: Capra
Type	: Capra aegagrus hircus.

## RESEARCH METHODS

This research was conducted in October-November 2019 at the Pathology Laboratory of the Veterinary Institute of Lampung. Lung organ sample qurban goats (*Capra aegagrus hircus*) were taken on the Eid al-Adha feast in August 2019 from the Baburrahman mosque in Tulus Rejo Village, Pekalongan District, East Lampung with a total of 13 samples in collaboration with the Veterinary Institute of Lampung. The qurban goat lungs that have been taken are fixed in a formalin solution with a ratio of 1:10 to avoid organ damage and get good histopathological observations. According to Sudatri *et al.*, (2016), the stages of making histopathological preparations, namely trimming, dehydration, embedding, cutting, staining, mounting, and reading the preparations under a trinocular microscope.

The flow chart of this research can be found at figure 1:



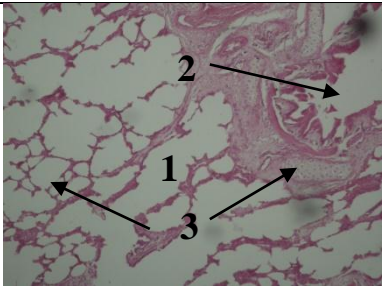
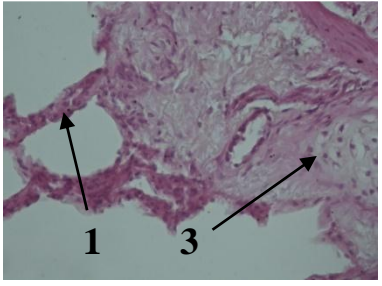
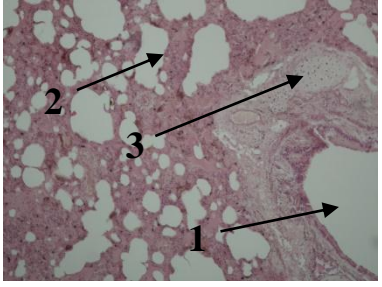
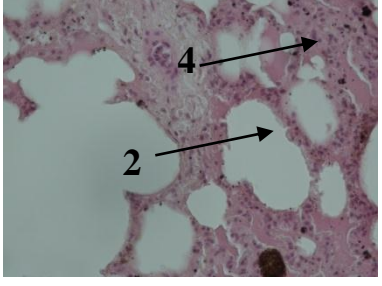
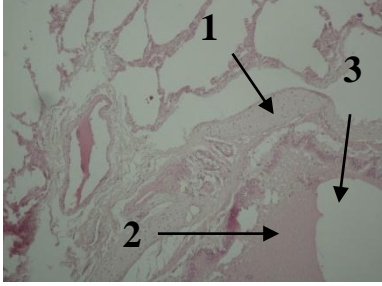


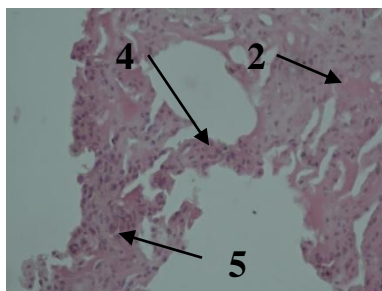
*Figure 1. Research Flowchart*

## RESULT

The observational data of a sample of qurban goats suspected of being infected with pneumonia from the Baburrahman mosque of Tulus Rejo Village, Pekalongan District, East Lampung, can be seen in Table 1:

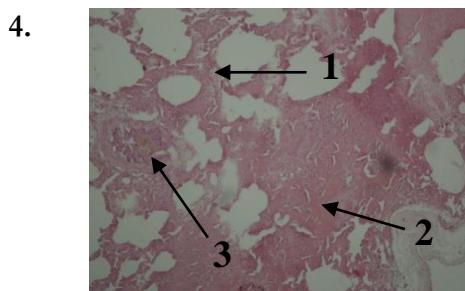
Table 1. Observation Table Of Lung Organ Of A Sacrificial Goat Suspected Of Being Infected With Pneumonia.

No.	Picture	Characteristic	Information
1.	 <p>A.</p>  <p>B.</p>	No inflammation, edema, or blood cells were found at 100X and 400X magnification.	Histopathology of normal organs. H&E (A) 100X, (B) 400X. Description: 1. septa alveoli 2. bronchi 3. cartilage
2.	 <p>A.</p>  <p>B.</p>	Thickening of the septa alveoli containing inflammation cells was found.	Histopathology of organs infected with acute multifocal interstitial pneumonia. H&E (A) 100X, (B) 400X. Information: 1. bronchi 2. thickening of the septa alveoli 3. cartilage 4. Inflammation cells
3.	 <p>A.</p>	Edema was found in the alveoli and there was a thickening of the alveoli containing inflammation cells.	Histopathology of organs infected with mild acute pulmonary edema. H&E (A) 100X, (B) 400X. Information: 1. cartilage 2. edema



B.

3. bronchi
4. thickening of the septa alveoli
5. Inflammation cells.



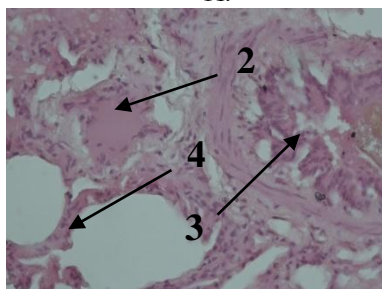
A.

Edema was found in the alveoli and there was a thickening of the alveoli containing inflammation cells.

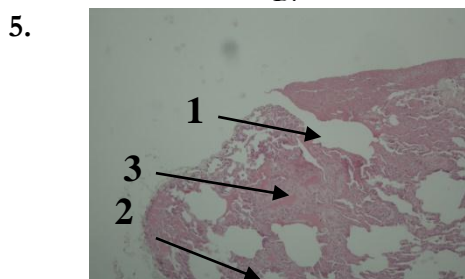
Histopathology of organs infected with mild acute pulmonary edema. H&E (A) 100X, (B) 400X.

Information:

1. thickening of the alveoli septa
2. edema
3. bronchioles
4. Inflammation cells.



B.



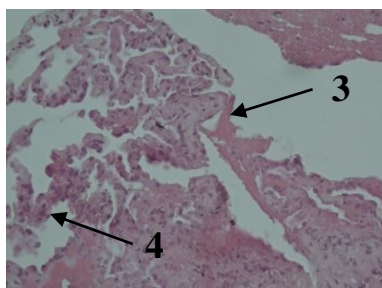
A.

Blood clots, edema, and thickening of the septa alveoli contain inflammation cells.

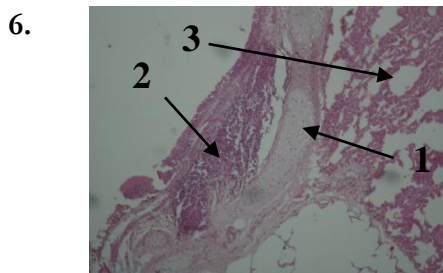
Histopathology of organs infected with mild pneumonia edema pulmonum and mild acute vocal hemorrhagic pneumonia. H&E (A) 100X, (B) 400X.

Information:

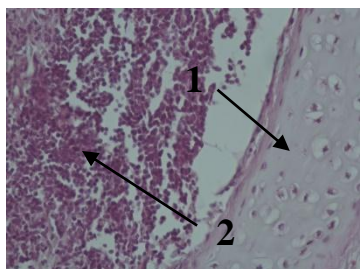
1. hemorrhage
2. thickening of the septa alveoli
3. edema
4. Inflammation cells.



B.



A.



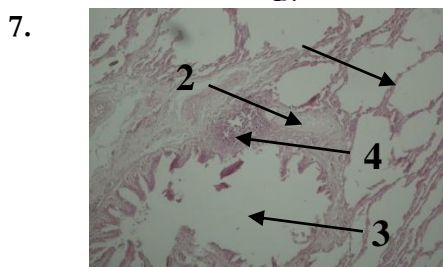
B.

Found a pile of inflammatory cells around the bronchi and thickening of the alveoli containing inflammatory cells.

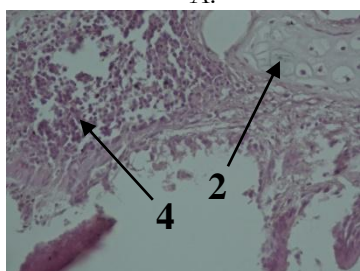
Histopathology of organs infected with mild-acute peri-bronchial vocal mild pneumonia. H&E (A) 100X, (B) 400X.

Information:

1. cartilage
2. Inflammation cells
3. thickening of septa alveoli.



A.



B.

Found a pile of inflammatory cells around the bronchi and thickening of the alveoli containing inflammatory cells.

Histopathology of organs infected with vocal acute peribronchial pneumonia. H&E (A) 100X, (B) 400X.

Information:

1. septa alveoli
2. cartilage
3. bronchi
4. Inflammation cells.

## DISCUSSION

From 13 samples of qurban goat lungs, there were 6 observations of qurban positive goats infected with pneumonia with 1 type of acute pneumococcal interstitialis pneumonia, 2 types of acute pneumonia vocal pulmonum edema, 1 type of mild pneumonia edema pulmonum and 1 type of mild pneumonia hemorrhagic vocal acute all at once, and 2 types of mild-bronchial vocal peri-bronchial mild pneumonia. This is proven by observations under a microscope with inflammation cell formation accompanied by thickening of the alveoli, edema, and blood. Whereas the other 7 samples were not infected with any type of pneumonia represented by sample No. 1, the

sample of the qurban goat lung organ that was infected with pneumonia was characterized by not finding any thickening of the septa alveoli containing inflammatory cells, edema, and hemorrhage.

Placement of livestock of various ages and animals in excess. Maximum limits in one enclosure can cause multiple spreads diseases caused by viruses, bacteria, and ect (Murtidjo, 1993). The maximum limit for the number of animals in a cage depends on the size of the cage used, so that livestock can still move freely. This is consistent with observational data showing that 7 samples of qurban goat lungs were positive infected by pneumonia. Microscopically, several samples of the qurban goat's lung organs

have been found to turn blackish red. The texture of the lung organs is no longer the same, but there are some sides that have begun to harden but do not form bubbly white nodules that contain pus.

According to Ermawati (2011), some viruses that cause pneumonia, namely, adenovirus, parainfluenza-3, and rhinovirus, and bacteria namely *Pasteurella multocida*, while according to Subronto (1985) also explain infections by germs *Pasteurella* sp. and *Mycoplasma* sp. usually take place acutely, while *Mycobacterium* sp. can cause chronic symptoms and granuloma formation.

According to Yuwono (2008), pneumonia sufferers are characterized by symptoms of coughing, and difficulty breathing or rapid breathing characterized by breathing frequency more than 40 times per minute. while according to Sarwono (2006), goats infected with pneumonia cause nasal symptoms from heavy to clear, suppurating pulses, fever, coughing, decreased appetite, tongue sticking out, breathing sounds like people grating, heavy or fast breathing, and excessive. Infected goats also look groaning, complaining, and gritting teeth due to pain.

Ressang (1984) explained that there were many inflammatory cells found in the septa and peri-bronchial and peri-vascular connective tissue in interstitial pneumonia. According to Rampengan (2014) and Susilo (2019), pulmonary edema shows a microscopic characteristic that the alveoli are filled with fluid so that gas exchange is impossible. accumulation of this fluid occurs excessively in the space between the alveoli. Ressang (1984) also explains that hemorrhagic pneumonia occurs due to rupture of blood vessels in the lungs. According to Kubiak et al. (2010), hemorrhage is an erythrocyte found in the lumen of the alveoli, while congestion is blood that comes out of the air space due to the filling of capillaries with excess blood. Ressang (1984) also explains peri-bronchial pneumonia showing a characteristic mucopurulent exudate in the bronchi and edema. Whereas Kumar et al. (2009) and Susilo (2019), bronchopneumonia shows the formation of many neutrophil inflammatory cells in the bronchi and bronchioli regions. The number of inflammatory cells that are formed, usually will form an abscess.

## CONCLUSION

The conclusions obtained from this study are about 7 negative samples were infected with pneumonia with the characteristic not found thickening of the alveoli containing inflammatory cells, edema, and blood. While 6 other qurban lung samples tested positive for pneumonia were characterized by thickening of the septa alveoli containing inflammatory cells, edema, hemorrhage, and inflammatory cells in the outer edge of the bronchus. Then from 13 samples of lung organs, 6 samples of qurban goat's lung organs were infected with pneumonia, so that 46% of samples were infected with the most types of pneumonia, namely pulmonary edema pneumonia and peri-bronchial pneumonia.

## SUGGESTION

A better examination of qurban goats is needed in the following year by giving officers an understanding that the qurban goat's lungs that have changed color and texture changes are not suitable for consumption, and conduct further tests using a bacterial isolation test to determine the type of bacteria causes of pneumonia infection so as to strengthen the diagnosis of the disease.

## REFERENCES

- Alimudin, S. 2019. Suhu di Lampung Timur Pada Saat Musim Kemarau. [Hasil Wawancara Pribadi]. 22 Desember 2019. Labuhan Ratu VII, Braja Harjosari.
- Ditjen PKH. 2017. Statistik Peternakan dan Kesehatan Hewan 2017 (Livestock and Animal Health Statistics 2017). Direktorat Jenderal Peternakan dan Kesehatan Hewan Kementerian Pertanian RI. Hal: 86.
- Corwin, E. J. 2001. Pathophysiology (Interpreting, Brahm, U.). EGC Issuer. Jakarta.

- Ermawati, D. 2011. Untung Menggiurkan dari Budidaya Kelinci. Yogyakarta. CV. Andi Offset.
- Fikri, B. A. 2016. Analisis Faktor Risiko Pemberian Asi Dan Ventilasi Kamar Terhadap Kejadian Pneumonia Balita. *The Indonesian Journal of Public Health*. Vol. 11 (1), 14–27.
- Hati, I. R. P. 2016. Effects of Ethanol Extract of Dragon Scales (*Pyrrosia piloselloides*) on the Maturation of Goat Ovarian Follicles (*Capra aegragus hircus*) by In-Vitro [Thesis]. Negri Islamic University (UIN). Malang.
- Kubiak, B.D., Albert, S.P., Gatto, L.A., Snyder, K.P., Maier, K.G., Vieau, C.J.,
- Roy, S., dan Nieman, G.F. 2010. Peritoneal Negative Pressure Therapy Prevents Multiple Organ Injury in A Chronic Porcine Sepsis and Ischemia/Reperfusion Model. *SHOCK Journal*. Volume 34(5): 525-534.
- Kumar, V., Cotran, R.S., Robbins, S.L. 2009. Buku Saku Dasar Patologi Penyakit Cetakan 1. EGC. Jakarta.
- Jaya, H, D.2017. Pneumonia Ancam Anak Saat Cuaca Ekstrem. <https://www.lampost.co/berita-pneumonia-ancam-anak-saat-cuaca-ekstrem.html>. Diakses pada 22 Desember 2019 pukul 20:47 WIB.
- Liu Y, Wang H, Chen M, Sun Z, Zhao R, Zhang L., Wang, H., Zhang, H., Wang, L., Chu, Y., Liu, Y., Ni, Y. 2008. Serotype distribution and antimicrobial resistance patterns of *Streptococcus pneumoniae* isolated from children in China younger than 5 years. *Diagnostic microbiology and infectious disease*. 61(3):256-631.
- Murtidjo, B. A. 1993. Memelihara Kambing Sebagai Ternak Potong Perah. Kanisius. Yogyakarta.
- Rampengan, S. H. 2014. Edema Paru Kardiogenik Akut. *Jurnal Biomedik*. Volume 6 (3): 149-156.
- Ressang, A. 1984. Patologi Khusus Veteriner. Team Leader IFAD Project: Bali.
- Sarwono, B. 2006. Beternak Kambing Unggul. Penebar Swadaya. Jakarta.
- Sendow, I., Syafriati, T., Wiedosari, E., dan Selleck, P. 2002. Infeksi Virus Parainfluenza Tipe 3 pada Kasus Pneumonia Kambing dan Domba. *JITV*. Vol. 7. No. 1. Bogor.
- Subronto, 1985. Ilmu Penyakit Ternak. Gadjah Mada University Press. Yogyakarta.
- Sudatri, N. W., Iriani S., Suartini, N. M., dan Yulihastuti, D. A. 2016. Penurunan Fungsi Hati Tikus Betina (*Rattus Norvegicus* L) Yang Diinjeksi White Vitamin C Dosis Tinggi Dalam Jangka Waktu Lama Ditinjau Dari Kadar Sgpt, Sgot Serta Gambaran Histologi Hati. *Journal of Biological Sciences*. ISSN 2302-5697. Vol. 3, No. 1, 44-51. Bali.
- Susilo, J. 2019. Ciri-Ciri Dari Masing-Masing Jenis Pneumonia. [Hasil Wawancara Pribadi]. 3 Oktober 2019. Laboratorium Balai Veteriner Lampung.
- Wahid, A., dan Imam, S. 2013. Keperawatan Medikal Bedah, Asuhan Keperawatan pada Gangguan Sistem Respirasi. *Trans Info Media*. Jakarta.



Yuwono, T. A. 2008. Faktor – Faktor Lingkungan Fisik Rumah Yang Berhubungan Dengan Kejadian Pneumonia Pada Anak Balita Di Wilayah Kerja Puskesmas Kawunganten Kabupaten Cilacap [Tesis]. Universitas Diponegoro. Semarang.