

THE EFFECT OF MANGROVE
(*Rhizophora apiculata*) BARK EXTRACT
ETHANOL ON HISTOPATHOLOGY
PANCREAS OF MALE WHITE RATS
SPRAGUE DAWLEY STRAIN EXPOSED
TO CIGARETTE SMOKE

By Evi Kurniawaty

1 THE EFFECT OF MANGROVE (*Rhizophora apiculata*) BARK EXTRACT ETHANOL ON HISTOPATHOLOGY PANCREAS OF MALE WHITE RATS SPRAGUE DAWLEY STRAIN EXPOSED TO CIGARETTE 1 MOKE

INTRODUCTION

1 One of the basic human rights that must be met is getting free access to good quality of air. Human needs about 10-20 m³ air per day. However, in some places the need for air cannot be met because of polluted air due to increased cigarette consumption. Cigarette is one of the air pollutants causing inadequate human air requirements.[1]

Cigarette smoke causes pathological conditions such as inflammation, proteolysis, and oxidative stress. Oxidative stress is a process of shifting the balance of oxidants and antioxidants that tend to shift to oxidants. Oxidative stress is caused by reactive oxygen species (ROS). ROS is an oxygen molecule produced from normal cell metabolism. In low to moderate concentrations, ROS is useful for cell physiology process. However, in high concentration, it can be detrimental, so that in the physiological state of the oxidative stress, it should be prevented.[2,3]

Previous studies had shown that *Rhizophora apiculata* contain different active compounds. The results from Gas chromatography-mass spectrometry (GC-MS) analyses indicated that mangroves have a number of natural antioxidants such as phenolics, alkaloids, glycosides, essential oils, and other organic compounds.[4]

MATERIAL AND METHODS

This research was an experimental study using a posttest-only control group design. Data was taken at the end of the study after treatment, the groups were considered similarly before being treated.

At the end of the study, the results in all three groups were compare

The independent variables in this study were bark stem extract given to white rats (*Rattus norvegicus*) male Sprague Dawley strain and exposure to cigarette smoke. The dependent variable in this study was a picture of pancreatic histopathology exposed to cigarette smoke. The intermediate variables that can be controlled were the types of mice, the age of mice, food mice, beverage mice, and dosage of mangrove bark extract. An uncontrollable intermediate variable is the absorption of mangrove stem extract in mice and rats response to cigarette smoke exposure.[5]

The sample in this study was male white rat pancreas (*Rattus norvegicus*) Sprague Dawley strain. This study used three treatment groups and each group consisted of 10 rats based on Federer's formula and drop out. Group one is a group that is given only regular food and drinks just like 2 other groups. Group two were rats given 2 cigarettes for 1 hour per day for 30 days. Group three were mice were given mangrove stem extract at dose 56,55 mg/kgBB and given 2 cigarettes for 1 hour per day for 30 days.[6]

Mangrove bark was extracted by using the maceration method. The bark was obtained from East Lampung shoreline. The part of the plant was separated between the stem, bark, and root. The bark of mangrove stems was washed and then dried in open air. As much as 600 grams of mangrove stem skin extract was washed and cut into pieces. The skin of mangrove stem was milled using grinding machine until it became powderous. Oil grazed *Simplicia* bark powder was immersed in a 95% ethanol solvent of 1.5 L for the first 6

hours and stirred occasionally, then continued for 18 hours. The mixture with 95% ethanol solvent was filtered with filter paper to obtain the

1 filtrate. The obtained filtrate was evaporated by rotatory evaporator 50°C. One ml of mangrove stem bark extracts were taken and then allowed to dry for 24 hours at room temperature. The dried yields were weighed to obtain the specific gravity and volume of 0.0872 g/ml and 52 ml, respectively. The dose of mangrove root bark extract used was 56.55 mg/kgBW. Thus the mangrove stem extract given to mice weighing 200 g was 11.31 mg.[7]

1 Cigarette smoke exposure was performed using an electric cigarette. The animal was terminated by cervical dislocation method by using chloroform anesthesia. Histopathologic examination of the pancreas was observed with 400x magnification in five fields of view. The interpretation was applied with score 0 (zero) if no inflammation of cell was found and score 1 if inflammation of cell was found.[8,9]

1 Statistical data analyses were performed using the Statistical Package for the Social Sciences (SPSS) program with bivariate analysis type. The statistical test used in this study was a chi-square test because this research has unpaired categorical comparative analysis. If the requirement of chi-square test is not met, then fisher test is used as alternative statistic test.

RESULTS

1 Three groups of histopathologic images were shown in Figures 1, 2 and 3. In the first group, the pancreatic parenchyma cells of rats in normal circumstances were shown by the pancreatic parenchymal cell arrestment with no massive necrosis cell, atrophy, edema, fibrosis, or inflammatory cell. In the second group, cells with edema and

1 atrophy and massive inflammatory cells were found. However, no cells were found to be necrotic. In the third group, cells that experienced edema and atrophy were still observed, but no necrosis cells were observed. In this group, fewer inflammatory cells were observed compared with the number of inflammatory cells in group two.

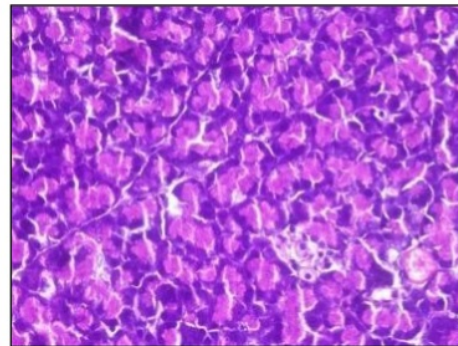
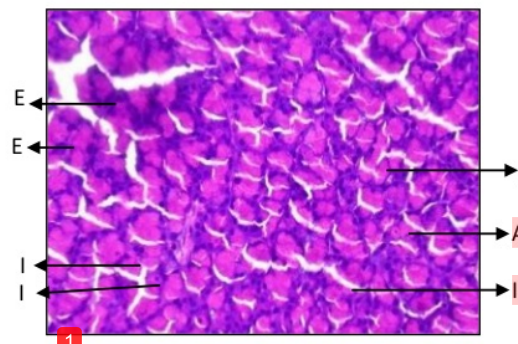
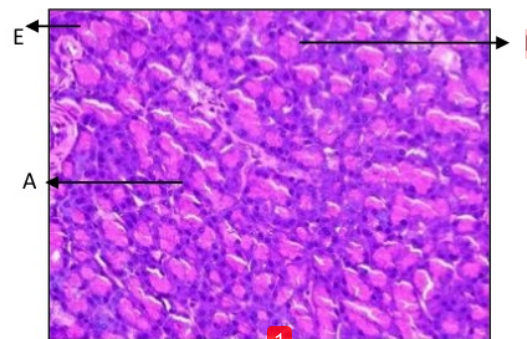


Figure 1. Group one



1 Figure 2. Group two (E: Edema; A: Atrophy; I: inflammatory cell)



1 Figure 3. Group three (E: Edema; A: Atrophy; I: inflammatory cell)

1 By employing univariate analysis, an average number of pancreatic inflammatory cells with 400x magnification in five fields of view were obtained. The number for group one, group two and group three were 0.40 ± 0.52 , 3.60 ± 0.69 and 2.10 ± 0.74 , respectively (Table 1).

Table 1. Histopathological Analysis of Rat Pancreas (Magnification 400x in five field of view)

Group	Mean \pm SD
Group 1 (control)	0,40 \pm 0,52
Group 2 (cigarette)	3,60 \pm 0,69
Kelompok 3 (ciagarette +mangrove)	2,10 \pm 0,74

1 An average number of pancreas inflammatory cells with 400x magnification in five fields of view were obtained by applying bivariate analysis. There were 3 cells or 50% with an expected value of less than 0.05. After applying the chi-square test, the requirements for the 2x2 table were not met so that fisher test was performed. The results were shown in tables 2, 3, and 4.

Table 2. Chi Square Test G1 and G2

	No inflammatory cell		Inflammatory cells		P Value
	n	%	n	%	
G1	10	100	0	0	0,001
G2	0	0	10	100	
Total	10	50	10	50	

1 Table 3. Chi Square Test G1 and G3

	No inflammatory cell		Inflammatory cells		P Value
	n	%	n	%	
G1	10	100	0	0	0,105
G3	7	70	3	30	
Total	17	85	3	15	

1 Table 4. Chi Square Test G2 and G3

	No inflammatory cell		Inflammatory cells		P Value
	n	%	n	%	
G2	0	0	10	100	0,002
G3	7	70	3	30	
Total	17	85	3	15	

1 The results showed significant differences between group one and two ($p < 0,05$), as well as groups two and three ($p < 0,05$). However, statistically, there was no significant difference between group one and three ($p > 0,05$).

DISCUSSION

Microscopic description showed that showed normal pancreatic parenchyma cells indicated by tightly arranged cells and the absence of necrotic cells, atrophy, edema, fibrosis, or massive inflammatory cells. Aquades was the material used in the treatment and without exposure to smoke cigarettes and mangrove leaf extract. Thus, aquades was not a material that acts as an aggressive factor in pancreatic cells.[6]

When group two was compared with group one, there was a significant difference statistically ($p < 0.05$). In group two, cells found to be edema and atrophy, but no cells were found to be necrotic. Massive inflammatory cells were also observed. This was consistent with previous studies that by employing a single clove cigarette for one hour in 30 days caused pancreatic cells damage in the form of atrophy, edema, but the absence of necrotic cells.[6]

The process of pancreatic histopathologic changes is caused by exposure to cigarette smoke compounds given to mice for 30 days. Exposure to

1

cigarette smoke contains two main compounds of nicotine and tar. Nicotine in cigarette smoke contains various types of free radicals such as nitric oxide and nitrite dioxide that convert oxygen into superoxide anions that will form hydrogen peroxide and subsequently hydroxyl radicals. The tar that acts as a smoke condensate and the total residue, enters the lungs as solid vapors. The type of free radicals contained from tar is a semiquinone that can reduce oxygen to superoxide anion. These free radicals result in the destruction of polyunsaturated fatty acids in the cell membranes and potentially lead to fragmentation of DNA that can be a risk for cancer cells formation.[10,11]

The process of inflammation is related to the presence of free radicals. The presence of free radicals can induce the formation of inflammatory radicals that can lead to further inflammation. An example is a nitric oxide, a radical produced by nitrite dioxide synthetase (iNOS) which acts as a second messenger in the inflammatory process. The formation of iNOS occurs as a response to inflammatory cytokines caused by free radicals. iNOS stimulates the formation of nitric oxide which results in further inflammatory processes.[12]

These results supported previous research that cigarettes can be an independent factor of pancreatic cell damage. In the past, cigarettes were known as cofactors of alcohol that resulted in the destruction of pancreatic cells. But after a retrospective cohort study, it was found that there was an average shift in the age of acute pancreatitis diagnosis. The diagnosis of pancreatitis in smokers stands five years earlier than nonsmokers. In another study with measurement of cigarette consumption with pack years, ie

the number of cigarettes per day multiplied by 20 years (20 pieces/pack). Smokers with pack years <12 had a relative risk (odds ratio) of 1.35. While in pack years 12-35 and > 35 each have a relative risk of 2.15 and 4.59.[11]

Based on microscopic observation, there was no significant different ($p>0,05$) when group three compared to group one. This result was consistent with previous studies using mangrove bark extract as an antioxidant in naphthalene induced hepatic mitochondria.[13]

In a study conducted using mangrove bark extract as an antioxidant in naphthalene-induced hepatic mitochondria showed DPPH activity of more than 50% at a dose of 56.55 mg/kgBW. Previous research also showed that antioxidant activity using DPPH and ABTS methods was the most optimal on the skin of mangrove stem. Antioxidant activity (IC₅₀) of mangrove stem skin extract measured by DPPH and ABTS methods were 3,31 $\mu\text{g mL}^{-1}$ and 18,47 $\mu\text{g mL}^{-1}$, respectively.[13,14]

The anti-inflammatory activity by tannins is related to the nature of the active compound as a secondary antioxidant that captures free radicals. The gallate structure, polygalloil glucose (PGG), has five groups of galloil ester groups that inhibit the expression of iNOS activity. PGG also acts as an anti-inflammatory by inhibiting the formation of prostaglandin E₂ (PGE₂). PGE₂ is inhibited by PGG formation by the inhibition mechanism of cyclooxygenase 2 (COX-2), an enzyme that will catalyze the process from arachidonic acid to PGE₂. [12,15]

1

CONCLUSION

This study concludes that the administration of mangrove stem extract (*Rhizophora apiculata*) ethanol 95% with dose 56,55 mg/kgBB potency to protect damage of pancreatic cells of white rat (*Rattus norvegicus*) Sprague Dawley strain induced exposure to cigarette smoke.

The future direction of this study is to test further toxic dose of mangrove stem extract (*Rhizophora apiculata*) against protection from parenchymal cell damage of pancreas. Another suggestion is to compare the effects of mangrove stem extract (*Rhizophora apiculata*) on mangrove stem extract with different species. Examination of antioxidant activity such as superoxide dismutase (SOD) and malondialdehyde (MDA) as well as anti-inflammatory activity such as tumor necrosis factor- α (TNF- α) are also important to explore.

THE EFFECT OF MANGROVE (*Rhizophora apiculata*) BARK EXTRACT ETHANOL ON HISTOPATHOLOGY PANCREAS OF MALE WHITE RATS SPRAGUE DAWLEY STRAIN EXPOSED TO CIGARETTE SMOKE

ORIGINALITY REPORT

93%

SIMILARITY INDEX

PRIMARY SOURCES

1 media.neliti.com
Internet

1877 words — 93%

EXCLUDE QUOTES OFF

EXCLUDE MATCHES OFF

EXCLUDE
BIBLIOGRAPHY OFF