

See discussions, stats, and author profiles for this publication at: <https://www.researchgate.net/publication/301484253>

# Testicular Function of Rats Treated with Water Extract of Red Ginger (*Zingiber officinale* var. *rubrum*) Combined with Zinc

Article · January 2016

DOI: 10.12691/jfnr-4-3-5

CITATION

1

READS

27

5 authors, including:



**Sutyarso Sutyarso**

Lampung University

17 PUBLICATIONS 12 CITATIONS

[SEE PROFILE](#)



**Mohammad Kanedi**

Lampung University

28 PUBLICATIONS 3 CITATIONS

[SEE PROFILE](#)

Some of the authors of this publication are also working on these related projects:



Study on the effect of plant extract of purwoceng (*Pimpinella alpina*) and dragon fruit (*Hylocereus undatus*) on the libido and aggressiveness of male mice. [View project](#)



Trace elements surrounding Krakatau Islands [View project](#)

# Testicular Function of Rats Treated with Water Extract of Red Ginger (*Zingiber officinale* var. *rubrum*) Combined with Zinc

Sutyarso<sup>1</sup>, Muhartono<sup>2</sup>, Susianti<sup>3</sup>, Hendri Busman<sup>1</sup>, Mohammad Kanedi<sup>1,\*</sup>

<sup>1</sup>Department of Biology, Faculty of Mathematics and Sciences, University of Lampung, Indonesia

<sup>2</sup>Department of Anatomical Pathology, Faculty of Medicine, University of Lampung, Indonesia

<sup>3</sup>Department of Histology, Faculty of Medicine, University of Lampung, Indonesia

\*Corresponding author: [wegayendi@yahoo.com](mailto:wegayendi@yahoo.com)

**Abstract** Ginger is suggested as an antioxidant, has androgenic as well as hypoglycemic effect, whereas zinc claimed as fertility supplement. However, scientific study on the effects of ginger along with zinc in combination is still very limited. Current study aims to investigate any possible effect of ginger extract combined with zinc on testicular function of male albino rats. Twenty-four male Wistar rats weighing 180-200g and aged 10-12 weeks were randomly grouped into four consisted of six rats. Group 1 treated with distilled water (control); group 2, 3 and 4 are the rats given 500 mg/kg of ginger extract plus consecutively of 0 mg/kg; 0.5 mg/kg and 1 mg/kg zinc sulfate. The testicular function variables measured were testosterone levels, sperm concentration, sperm quality, and spermatogenic cell counts. The results showed that serum testosterone levels, sperm count, percentage of sperm viability and motility was higher in the mice given a combination of ginger extract and zinc compared with controls ( $P < 0.01$ ). Conversely the percentage of abnormal sperm morphology was decreased ( $P < 0.01$ ). Moreover, rats group receiving oral combination of ginger extract and zinc significantly showed an increase in the pre-leptotene and pachytene spermatocytes, and spermatids ( $P < 0.01$ ), but showed no significant difference in the spermatogonia cell counts ( $P > 0.05$ ). In conclusion, water extract of red ginger combined with zinc, administered orally potentially enhance testicular function including steroidogenesis and spermatogenesis in male rats.

**Keywords:** ginger, zinc, spermatogenesis, testosterone

**Cite This Article:** Sutyarso, Muhartono, Susianti, Hendri Busman, and Mohammad Kanedi, "Testicular Function of Rats Treated with Water Extract of Red Ginger (*Zingiber officinale* var. *rubrum*) Combined with Zinc." *Journal of Food and Nutrition Research*, vol. 4, no. 3 (2016): 157-162. doi: 10.12691/jfnr-4-3-5.

## 1. Introduction

Ginger (*Zingiber officinale*) has been used as a medicine to treat a variety of diseases around the world since time immemorial. The active ingredients of rhizomes and leaves of ginger like zingerone, gingerdiol, zingibrene, gingerol and shogaol known to have antioxidant activity [1]. These ingredients particularly gingerol and shogaol have shown a protective effect on the liver prominent diabetes, kidney, eye, and nervous system complications [2]. Furthermore, studies with animal models suggest that ginger is generally useful as an antioxidant [3], and has androgenic effects [4] and hypoglycemic effects [5].

Natural antioxidants can protect the molecule and cell by suppressing the oxidation. In animal subject antioxidant could improve sperm quality [6]. Ginger is proven to have a protective effect against nucleic acid damage induced by  $H_2O_2$  and improve the quality of sperm parameters [7], pro-fertility and androgenic [8], and chemo-protective against toxic substances, such as aspartame, in male rats [9]. By considering the anti-diabetic and pro-fertility properties of ginger extract,

drink of ginger rhizomes is recommended for diabetes patients with sexual dysfunction.

Zinc (Zn) is an essential trace element for living organisms, because more than 300 enzymes depend on zinc for its function. It also plays an important role in nucleic acid replication, transcription and protein synthesis, cell division and differentiation [10] and plays an important role regeneration of the damaged cells.

Moreover, zinc is suggested as an important component of the antioxidant defense system [11], and it was also revealed to inhibit generation of reactive oxygen species and enhance the activity of antioxidant pathways. [12]. Conversely, zinc deficiency increases lipid peroxidation in various tissues of rat, whereas Zn supplement corrects the disorder [13].

In rat, zinc supplementation bring about weight loss, increase the number of spermatogenic cell and promote it to develop into spermatid cells in the testis [14]. In the reproductive system, deficiency of zinc paves the way for the destruction of cells in the testis of rat [15].

Other research findings suggested that zinc supplements can improve testicular damage due to lead induction and maintain normal spermatogenesis process [16]. Zinc is known to be involved in maintaining the normality of

testes, epididymis, prostate function and male fertility allegedly due to its effect on both spermatogenesis and testosterone production by the Leydig cells [17].

Effect of ginger or zinc has been widely studied separately, but the effects of both substances in combination had not been studied. The current study, therefore, was set and aimed to determine the effect of red ginger extract in combination with zinc on the testicular function of rat.

## 2. Material and Methods

### 2.1. Plant Material and Extraction

Plant material of red ginger (*Zingiber officinale* var *rubrum*.) was collected from local farmers in Gisting, the District of Tanggamus, Lampung Province, Indonesia. Taxonomic identification of the plant was conducted by a professional botanist at the Herbarium Bogorienses, Indonesian Institute of Sciences, Bogor, Indonesia. The rhizomes cut into thin slices and then sun-dried between 10:00 to 12:00 o'clock. After being milled, the rhizome powder macerated indistilled water for 48 hours at room temperature and filtered. Lastly, the macerate was evaporated to obtain a dry powder extract of ginger for further use.

### 2.2. Experimental Animals and Treatment

Twenty-four albino male Wistar rats weighing 180-200g, aged 10-12 weeks, obtained from PT Indoanilab Bogor, Indonesia. Animals were placed in cages (one animal per cage) at room temperature, under controlled environmental conditions, 12/12 hour light/dark cycle, and given water and food *ad libitum*.

By using a completely randomized design, the animals were grouped into four groups consisted of 6 rats. Group 1 received 1ml of distilled water; group 2 given 500 mg/kg of ginger extract; group 3 treated with 500 mg/kg of the extract and 0.5 mg/kg zinc sulfate; and group 4 fed with 500 mg/kg of extract and 1 mg/kg of zinc. The zinc sulfate used in this study is a zinc sulfate heptahydrate ( $ZnSO_4 \cdot 7H_2O$ ) from Merck.

The dosage of ginger extract used in this study refers to the work of [8], while the zinc sulfate dose refers to the dosage applied by [16]. All of the test materials were administered daily via oral for 28 days.

### 2.3. Blood Sampling and Surgical Procedure

To get a sample of blood and the testes, the rats were sacrificed after the animals being deeply anesthetized using ether. Blood sample was collected by cardiac puncture and allowed to clot at room temperature for 45 minutes. Sera then separated by centrifugation at 2500 rpm for 15 minutes and kept frozen at  $-20^\circ C$  for hormone assays.

Testis and epididymis were taken by dissecting the peritoneal cavity at the posterior part of the abdomen. Any excess fat or connective tissue removed from the sampled organs, and then both testis and epididymis weighed using analytical-density digital balance with readability of 0.0001g.

### 2.4. Testosterone Assays

Total concentration of testosterone was determined at the Department of Physiology, Faculty of Medicine University of Indonesia, Jakarta, using a double antibody RIA (*radio immunoassay*) kit from DPC-USA (*diagnostic product corporation*).

### 2.5. Testicular Functions Assessment

Testicular function parameters assessed in this study are: testis weight, epididymis weight, diameter of seminiferous tubule, spermatocyte count, spermatid count, spermatozoa concentration, sperm motility and normal morphology.

Testes and epididymis removed and weighted using analytical-density digital balance with readability of 0.0001g. Semen in the epididymis was squeezed and diluted with physiological saline. Spermatozoa was counted using a Neubauer's haemocytometer under a light microscope at 400x magnification and expressed as million/ml of suspension. Quantitative epididymal sperm motility expressed as an index determined by counting both motile and immotile spermatozoa per unit area.

Sperm morphology was assessed from a smear of the epididymal filtrate prepared on a clean glass slides by addition of a drop of 1% eosin. After the object dried observation done under a light microscope at 400x magnification and abnormalities of either head or tail were noted.

To assess the seminiferous tubular diameters and spermatocyte as well as spermatid count, left testis from each mouse was fixed in Bouin's solution. Transverse sections of the organs were cut at 5  $\mu m$  and stained with hematoxylin and eosin. The tubular diameter was determined by measuring the width of the tubules using oculometer. Spermatocytes and spermatids counts were done at 10 seminiferous tubules of each experimental unit and then averaged.

In this study, the histo-morphometric parameters namely seminiferous tubules (STD), spermatogonia (Sg), preleptotene spermatocytes (PLSc), pachytene spermatocytes (PSc), and spermatid cells (Sd) observed and assessed using Olympus microscope (Olympus-BX53) and Olympus Stream-Application Software Version 1.7 (Art. Code: 5-648-111-11-4).

### 2.6. Statistical Analysis

The data, presented as Mean  $\pm$  SD, was analyzed with a one-way ANOVA. Means were separated using Least Significance Difference (LSD) test. All of the statistics that applied are programmed in IBM SPSS (Version 21).

## 3. Results

The effects of water extract of red ginger combined with zinc on body weight, testis weight, epididymis weight, and testosterone levels of male rats are presented in Table 1. Among the parameters mentioned, only testosterone levels that showed a significant difference between controlled and treated rats, and specifically between the rats fed only ginger extract and the rats that fed with the combination of ginger and zinc ( $p < 0.01$ ). This figure shows that the administration of a combination

of ginger rhizome extract together with zinc in rats markedly increased serum testosterone levels.

Sperm parameters of rats fed ginger extracts with or without zinc for 28 days are described in Table 2. All sperm parameters namely sperm count, sperm viability,

sperm motility, and sperm morphology markedly indicate a positive effect of ginger extract with and without zinc supplement ( $p < 0.01$ ) on the reproductive function of male rats. Specific to sperm motility, the effect of zinc supplementation even increased with the dose administered.

**Table 1. Effects of red ginger extract combined with zinc on body weight, testis weight and testosterone levels of male rats**

Parameters	Group 1 (Control)	Group 2 (500 mg/kg of ginger extract)	Group 3 (500 mg/kg of ginger extract + 0.5mg/kg of zinc)	Group 4 (500 mg/kg of ginger extract + 1mg/kg of zinc)	ANOVA (p-value)
Initial body weight (g)	192.50±7.58 <sup>a</sup>	191.67±6.83 <sup>a</sup>	193.33±7.53 <sup>a</sup>	191.33±7.52 <sup>a</sup>	.975
Final body weight (g)	205.00±7.07 <sup>a</sup>	205.83±5.85 <sup>a</sup>	208.33±4.08 <sup>a</sup>	210.83±8.33 <sup>a</sup>	.323
Testis weight (g)	1.76±.30 <sup>a</sup>	1.82±.42 <sup>a</sup>	1.84±.20 <sup>a</sup>	1.94±.24 <sup>a</sup>	.757
Epididymis weight (g)	0.395±0.053 <sup>a</sup>	0.414±0.056 <sup>a</sup>	0.411±0.079 <sup>a</sup>	0.432±0.064 <sup>a</sup>	.793
Total testosterone (ng/ml)	2.10±0.94 <sup>a</sup>	4.75±1.33 <sup>b</sup>	6.74±1.16 <sup>c</sup>	7.09±1.39 <sup>c</sup>	.000

Values are mean ± SD; values of each parameter that share the same superscript are not significantly different at  $\alpha=0.05$  using LSD test.

**Table 2. Effects of red ginger extract combined with zinc on sperm parameters of male rats**

Parameters	Group 1 (Control)	Group 2 (500 mg/kg of ginger extract)	Group 3 (500 mg/kg of ginger extract + 0.5mg/kg of zinc)	Group 4 (500 mg/kg of ginger extract + 1mg/kg of zinc)	ANOVA (p-value)
Sperm concentration ( $\times 10^6$ /ml)	18.69±2.81 <sup>a</sup>	26.05±4.55 <sup>b</sup>	42.01±3.78 <sup>c</sup>	41.43±3.74 <sup>c</sup>	.000
Sperm viability (%)	69.77±3.56 <sup>a</sup>	77.37±5.89 <sup>b</sup>	86.34±6.35 <sup>c</sup>	88.18±4.55 <sup>c</sup>	.000
Sperm motility (%)	66.71±3.90 <sup>a</sup>	70.96±3.26 <sup>b</sup>	77.98±3.19 <sup>c</sup>	82.69±4.03 <sup>d</sup>	.000
Sperm abnormal (%)	9.13±1.76 <sup>a</sup>	7.24±1.32 <sup>b</sup>	5.19±1.36 <sup>c</sup>	4.98±1.19 <sup>c</sup>	.000

Values are mean ± SD; values of each parameter that share the same superscript are not significantly different at  $\alpha=0.05$  using LSD test.

The histomorphometric data, as shown in Table 3, indicated that only the number of spermatogonia was not significantly different between groups ( $P>0.05$ ) but the diameter of seminiferous, the number of spermatocytes and spermatids cell are significantly increased in the treated rats compared to that of controlled ( $P<0.01$ ).

However, among the spermatogenic cells, only the spermatid cell counts which indicate that there was the effect of zinc supplement on spermatogenesis in rats. While in the spermatocyte cells, both pre-leptotene and pachytene, the effect of zinc added to the ginger extract is not significant.

**Table 3. Effects of red ginger extract combined with zinc on histomorphometry of seminiferous tubules of male rats**

Parameters	Group 1 (Control)	Group 2 (500 mg/kg of ginger extract)	Group 3 (500 mg/kg of ginger extract + 0.5mg/kg of zinc)	Group 4 (500 mg/kg of ginger extract + 1mg/kg of zinc)	ANOVA (p-value)
Seminiferous diameter ( $\mu$ m)	288.39±8.21 <sup>a</sup>	291.66±5.39 <sup>a</sup>	314.41±8.19 <sup>b</sup>	311.65±3.82 <sup>b</sup>	.000
Spermatogonia	7.55±1.86 <sup>a</sup>	7.66±1.46 <sup>a</sup>	8.16±1.03 <sup>a</sup>	7.80±1.62 <sup>a</sup>	.907
Preleptotene spermatocyte	16.97±2.01 <sup>a</sup>	21.20±2.53 <sup>b</sup>	22.68±3.72 <sup>b</sup>	20.76±2.07 <sup>b</sup>	.010
Pachytene spermatocyte	21.51±4.24 <sup>a</sup>	31.28±4.69 <sup>b</sup>	36.25±4.84 <sup>b</sup>	34.04±2.66 <sup>b</sup>	.000
Spermatid	76.66±15.28 <sup>a</sup>	118.24±15.32 <sup>b</sup>	138.58±17.10 <sup>c</sup>	131.43±9.09 <sup>c</sup>	.000

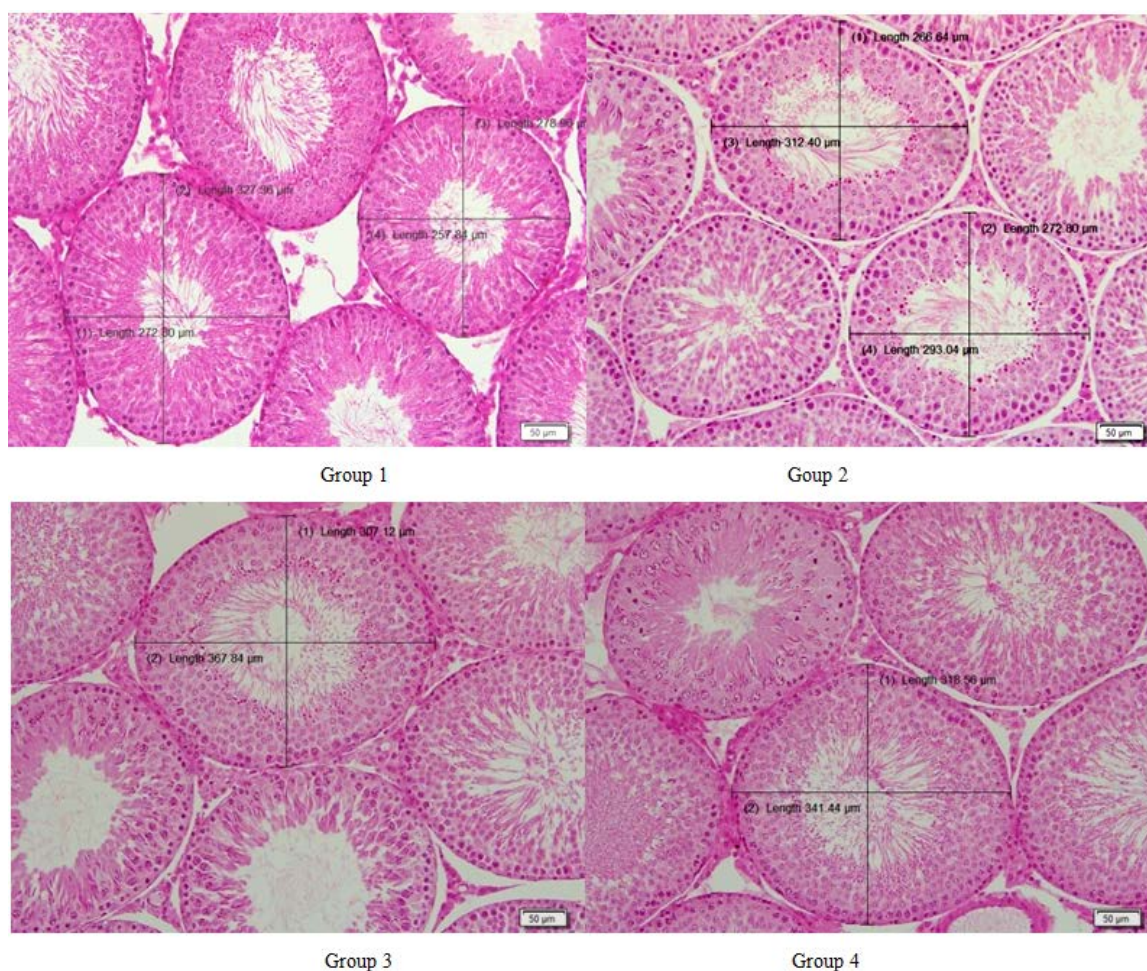
Values are mean ± SD; values of each parameter that share the same superscript are not significantly different at  $\alpha=0.05$  using LSD test.

The histomorphological difference between seminiferous tubules of rats that fed distilled water (Group 1), fed only ginger extract (Group 2), fed 500 mg/kg of ginger extract plus 0.5 mg/kg of zinc (Group 3), and fed 500 mg/kg of ginger extract plus 1mg/kg of zinc (Group 4) respectively are visualized in Figure 1.

Subsequently, bivariate correlation test was performed to determine the relationship between the increases in testosterone with testicular function (Table 4). Apparently, all sperm parameters (dependent variable) significantly can be accounted for by testosterone levels (independent variable) ( $P<0.01$ ) with a strong manner ( $0.641 < r < 0.845$ ).

**Table 4. Pearson bivariate correlation test (r) between testosterone levels (independent variable) and sperm parameters (dependent variable) of rats given orally ginger extract combined with zinc**

Dependent Variables	Independent Variables		
	Total testosterone (ng/ml)		
	N	r	P-value
Spermatid	24	.705	.000
Spermatid degeneration (%)	24	-.802	.000
Sperm concentration (106/ml)	24	.845	.000
Sperm viability (%)	24	.792	.000
Sperm motility (%)	24	.715	.000
Sperm abnormal (%)	24	-.641	.001
Seminiferous tubule diameter ( $\mu$ m)	24	.671	.000



**Figure 1.** The diameter of seminiferous tubules and spermatogenic cell counts of male rats get different treatment. Group 1, the control rats, showed normal seminiferous tubules with normal spermatogenesis; Group 2, received ginger extract of 500 mg/kg without zinc, showed a normal spermatogenesis and a better association of spermatogenic cells; Group 3, given a mixture of 500 mg/kg and 0.5 mg/kg of zinc, showed a normal spermatogenesis, better association and higher density of spermatogenic cells, Group 4, that given a mixture of 500 mg/kg and 1 mg/kg of zinc, showed normal spermatogenesis, very good association, spermatogenic cells denser and lumen contains full mature spermatozoa

## 4. Discussions

In mammals, the testes have a dual function: spermatogenesis and steroidogenesis. However, some conditions can interfere with spermatogenesis and reduce sperm quality and production. Various factors such as medication, chemotherapy, toxins, polluted air, lack of nutrients and vitamins can adversely affect spermatogenesis and sperm production [18]. Similarly, in a natural or normal spermatogenesis, apoptosis can be taken place. Normal spermatogenesis is set appropriately and the balance between cell proliferation continuously and apoptosis [19].

Current findings show that the administration of ginger extract combined with zinc (Zn), increases spermatogenesis in mice with normal reproductive function. It can be assumed that the high effectiveness of ginger on spermatogenesis along with zinc in this study is due to such an agent allegedly works through hypothalamus-pituitary-gonad axis. As has been proved that ginger treatment cause significant increase in FSH, LH and testosterone serum of infertile patients [20].

In animal models, ginger also could act as antioxidants [21], whereas the oxidative stress it self is an inducer of apoptosis [22]. Many agents that induce apoptosis is

oxidants or stimulators of cellular oxidative metabolism. Conversely, many inhibitors of apoptosis have antioxidant activity or increase cellular antioxidant defenses system [23,24,25]. Furthermore, ginger showed antioxidant properties because it managed to increase superoxide dismutase and catalase activity in rat testis which would then optimize testicular function [21,26].

This study managed to show that a combination of ginger extract and zinc works mutually reinforcing in the process of spermatogenesis and steroidogenesis. The presumption is referred to the fact that testosterone, spermatocyte and spermatid, sperm concentration and sperm quality (viability, motility, and normal morphology) in treated rats showed a better trend than that of normal control group. The other interesting thing found by current study is the percentage of degenerate spermatid in the treatment group is lower and allegedly be associated with the decrease in the rate of apoptosis. In other word, the increasing concentration of spermatozoa is due to inhibitory effects of ginger extract and zinc on apoptosis.

The increasing quantity and quality of sperm in the study is consistent with the study reported by [27] that the administration of *Zingiber officinale* increases the antioxidant enzyme activity of testis and is androgenic. In addition, ginger significantly lowered lipid peroxidation by maintaining the activity of antioxidant enzymes such as

superoxide dismutase, catalase and glutathione peroxidase [28] that allows a better sperm quality in mice.

Effect of zinc supplementation along with ginger extract in this study clearly seen in testosterone levels (Table 1), sperm concentration, viability and motility (Table 2), and sperm morphology (Table 3). Current findings confirm the previous studies on the biological role of zinc in living organism. Reference [29] suggested that zinc (Zn) is needed for more than 300 different biological processes, including DNA transcription, protein translation, cell proliferation and differentiation, and apoptosis.

From the perspective of reproductive function, zinc is proven to play a key role in spermatogenesis [30]. Zn found mainly in the Leydig cells, type-B spermatogonia and spermatids and is essential for the production and secretion of testosterone from the Leydig cells as well [31]. Along with follicle stimulating hormone, Zn is suggested as the key regulator of spermatogenesis [32]. Conversely, the deficiency of Zn causing the reduced function of the luteinizing hormone receptors, reducing the synthesis of steroid, and damage to the Leydig cells [33,34,35]. Zinc is quite high in the developing spermatocytes because Zn is required for DNA condensation and meiosis [36] and facilitates DNA packaging in spermatids [37].

Referring the data in Table 4 it is markedly that all sperm parameters related to the testosterone concentration changes. In vertebrate, especially mammals, both spermatozoa and testosterone are produced in reproductive tract, whereas the reproductive endocrine systems in male comprises of hypothalamus, anterior pituitary and testes [38], so that, it is very likely that ginger extract in combination with zinc works on hypothalamic-pituitary-gonadal (HPG) system.

Lastly, the positive trend of supplementation effect of zinc combined with the ginger extract is shown by Figure 1. The combination of ginger and zinc (Group 3 and 4) make the spermatogenic cells denser and better in association. These facts confirmed that zinc, as well as selenium, folic acid, or vitamin is involved in spermatogenesis, sperm maturation and development. Also, confirmed that Zn functioned as an antioxidant that protect sperm cells from oxidative damage during the entire production of sperm took place [38].

## 5. Conclusion

In conclusion, the combination of water extract of red ginger and zinc effectively improve testicular function including steroidogenesis and spermatogenesis in rats and thus the addition of zinc into ginger extract can be used as the potential fertility herbs in male.

## Acknowledgement

Authors are grateful for the research sponsorship from The Faculty of Medicine, University of Lampung, Indonesia.

## Conflict of Interest

Authors declare no conflict of interest.

## References

- [1] Zancan KC, Marques MO, Petenate AJ, Meireles MA, "Extraction of ginger (*Zingiber officinale* Roscoe) oleoresin with CO<sub>2</sub> and co-solvents: A study of the antioxidant action of the extracts," *J Supercri Fluids*. 24:57-67. 2002.
- [2] Li, Y, Tran VH, Duke CC, Roufogalis BD. Preventive and protective properties of *Zingiber officinale* (Ginger) in diabetes mellitus, diabetic complication, and associated lipid and other metabolic disorder: A Brief Review. Evidence-Based Compl Alter Med. Hindawi Publishing Co 2012, article ID 516870, 10 pages.
- [3] Sekiwa Y, Kubota K, Kobayashi A. "Isolation of novel glycosides from ginger and their atioxidative activity," *J Agric Food Chem* 8:373-379. Feb.2000.
- [4] Kamtchouing P, Mbongue-Fandio GY, Dimo T, Jatsa HB. [Evaluation of androgenic activity of \*Zingiber officinale\* extractin male rats.](#) *Asian J Androl* 2002;4.:299-301.
- [5] Hafez DA. [Effect of extracts of ginger goots and cinnamon bark on fertility of male diabetic rats.](#) *J Am Sci*. 6:940-47.2010.
- [6] Yang HS, Han DK, Kim JR, Sim JC., "Effet of alpha-tocopherol on cadmium induced-toxicity in rat testis and carcinogenesis," *Korean Med J*. 21:445-451. 2006.
- [7] Khaki A, Fathiazad F, Nouri M Khaki A, Chelar C, ozanci, Ghafari-Novin M, Hamadeh M. "The Effects of Ginger on Spermatogenesis and Sperm parameters of Rat.," *Iranian J Reprod Med* 7:7-12.2009.
- [8] Morakinyo AO, Adeniyi OS, Arikawe AP. "Effects of *Zingiber officinale* on reproductive functions in the male rat." *African J Biomed Res*. 11:329-334. Sept. 2008;
- [9] Hozayen WG, Soliman HA, Abou-Seif HS. "Study of the chemopreventive effects of *Zingiber officinale* roots against aspartame induced testicular toxicity in rat model," *J Phys Pharm Adv*. 4:360-367.May 2014.
- [10] Croxford TP, McCormick NH, Kelleher SL. "Moderate Zinc Deficiency Reduces Testicular Zip6 and Zip10 Abundance and Impairs Spermatogenesis in Mice," *J Nutr*. 141: 359-365. Jan. 2011.
- [11] Özaslan M., Kılıç I.H., Aytekin T., Güldür M.E. and Bozkurt A.I. "Investigation of Antioxidant Effect of Zinc Biochemically and Histopathologically in Rats". *Biotechnol. & Biotechnol. Eq*. 2005; 19 (2): 136-143.
- [12] Zhou Z., Wang L., Song Z., Saari J.T., McClain C.J. and Kang Y.J. "Zinc Supplementation Prevents Alcoholic Liver Injury in Mice through Attenuation of Oxidative Stress." *Am J Pathol*. 2005 Jun; 166 (6): 1681-1690.
- [13] Saxena DK, Murthy RC, Singh C, Chandra SV. "Zincprotects testicular injury induced by concurrent exposure to cadmium and lead in rats." *Res Comm Chem Pathol Pharmacol* 1989;64:317-329May 1989.
- [14] Abdella AM, Elabed BH, Bakhiet AO, Gadir WSA, Adam SEI. "In vivo Study on Lead, Cadmium and Zinc Supplementations on Spermatogenesis in Albino Rats," *J Pharmacol Toxicol*. 6(2):141-148. 2011.
- [15] Shaheen AA, El-FattahAA. "Effectofdietary zinc onlipid peroxidation, glutathione, protein levels and superoxide dismutase activity in rat tissues." *Int J Biochem Cell Biol*. 27:89-95. Jan.1995.
- [16] Fadda WA, Mansour FK, El-Habiby MM, El-Safty FA. "Histological and immunohisto-chemical study on the effect of lead on development of testis in albino rat and role of zinc supplementation," *Menoufiya Med J*. 21(1):77-90. 2008.
- [17] Zorbass YG, Yaroshenko YAN, Kuznetsov NK, Ivanov AL. "Daily zinc supplementation effect on zinc deficiency in rats during prolonged restriction of motor activity," *Biol Trace Element Res* . 60:101-113.1997.
- [18] Mosher WD and Pratt WF. "Fecundity and infertility in the United States: Incidence and trends," *J Fertil Steril*. 56:192-193. 1991.
- [19] Allan DJ, Harmon BV and Roberts SA. "Spermatogonial apoptosis has three morphologically recognizable phases and shows no circadian rhythm during normal spermatogenesis in the rat," *Cell Proliferation*. 25:241-250. May 1992.
- [20] Mares WAAK and Najam WS. "The effect of ginger on semen parameters and serum FSH, LH & testosterone of infertile men," *Tikrit Med J*. 18:322-29. 2012.
- [21] Rasyidah TI, Suhana S, Nur-Hidayah A, Kaswandi MA, Noah RM. "Evaluation of antioxidant activity of *Zingiber officinale*

- (ginger) on formalin-induced testicular toxicity in rats," *J Med Bioeng*.3(3):149-153.. Sept. 2014.
- [22] Chandra J, Samali A, Orrenius S. "Triggering and modulation of apoptosis by oxidative stress," *Free RadicBiol Med*. 29:323-32.Aug.2000.
- [23] Qin F, Rounds N, Mao W, Kawai K, Liang C. "Antioxidants vitamins prevent cardiocyte apoptosis produced by norepinephrine infusion in ferrets," *Cardiovasc Res*. 51:736-48.Sept. 2001.
- [24] Khaki A, Khaki AA, Hajhosseini L, Golzar FS, Ainehchi N., "The anti-oxidant effects of ginger and cinnamon on spermatogenesis dysfunction of diabettes rats," *African TraditComplAltern Med* 11:1-8. 2014.
- [25] Sakr SA and Badawy GM. "Effect of ginger (*Zingiber officinale*R.) onmetiram-inhibited spermatogenesis and induced apoptosis in albino mice,"*J App Pharm Sci*.01(04). 131-136.2011.
- [26] Morakinyo AO, Achema PU, Adegoke OA. "Effect of *Zingiber officinale* (Ginger) on sodium arsenit-induced reproductive toxicity in male rats," *Afr J Biomed Res*. 13:39-45.2010.
- [27] Aleissa MS. "Effet of ginger supplements on some reproductive parameters and spermatogenesis of mice," *Indian J Fund Appl Life Sci*. 4:271-77.2014.
- [28] Morakinyo AO, Oludare GO, Aderinto OT, Tasdup A. "Antioxidant and free radical scavenging activities of aqueous and ethanol extracts of *Zingiber officinale*,"*Biol Med*. 3:25-30.2011.
- [29] Prasad AS, Schulert AR, Miale A Jr, Farid Z, Sandstead HH. "Zinc and iron deficiencies in male subjects with dwarfism and hypogonadism but without ancylostomiasis, schistosomiasis or severe anemia," *Am J Clin Nutr*.12:437-44. Jun.1963.
- [30] Kellokumpu S, Rajaniemi H. "Effect of zinc on the uptake of human chorionic gonadotropin (hCG) in rat testis and testosterone response in vivo,"*Biol Reprod.*; 24:298-305.1981.
- [31] McClain CJ, Gavalier JS, Van Thiel DH. "Hypogonadism in the zinc deficient rat: localization of the functional abnormalities," *J Lab Clin Med*. 104:1007-15. Dec.1984.
- [32] Ruwanpura SM, McLachlan RI, Meachem SJ. "Hormonal regulation of male germ cell development," *J Endocrinol*. 205:117-31.May 2010.
- [33] Hesketh JE. "Effects of dietary zinc deficiency on Leydig cell ultrastructure in the boar," *J Comp Pathol*. 92:239-47. 1992.
- [34] Oteiza PL, Olin KL, Fraga CG, Keen CL. "Oxidant defense systems in testes from zinc-deficient rats," *ProcSocExpBiol Med* 213:85-91. Oct. 1996.
- [35] Oteiza PI, Clegg MS, Keen CL. "Short-term zinc deficiency affects nuclear factor-κB nuclear binding activity in rat testes," *J Nutr*.131:21-26. 2001.
- [36] Kundu TK, Rao MRS. "Zinc dependent recognition of a human CpG island sequence by the mammalian spermatidal protein TP2," *Biochemistry* 35:15626-32. Dec 1996.
- [37] Pradeepa MMRM. "Chromatin remodeling during mammalian spermatogenesis: role of testis specific histone variants and transition proteins,". *Soc Reprod Fertil Suppl* 63:1-10. 2007.
- [38] Cheah Y and Yang W. "Functions of essential nutrition for high quality spermato-genesis,"*Adv Biosci Biotech*. 2:182-97. Aug. 2011.